



OTOPLASTY SURGICAL TECHNIQUE

Caroline Banks & Mack Cheney

Otoplasty is defined as surgical correction of external auricular deformities. Correction of the **prominent ear**, or **prominauris**, the most common auricular deformity with an estimated incidence of 0.5% to 15% in newborns, and is the focus of this chapter.¹ Children and adults with auricular deformities may suffer significant social and psychological trauma. Dramatic psychosocial improvements after otoplasty are well-documented.^{2,3}

Anatomy

Surgical correction of the prominent ear requires a thorough understanding of the complex anatomy of the auricle. The external ear is composed of fibroelastic cartilage covered by perichondrium. The skin is adherent to the perichondrium anteriorly. Posteriorly the skin is less adherent due to a loose layer of areolar connective tissue above the perichondrium. The lobule does not contain cartilage and is composed of thicker skin and connective tissue.

The anatomic elements of the ear are the root of the helix, helix, antihelix, superior (posterior) crus of antihelix, inferior (anterior) crus of antihelix, tragus, antitragus, triangular fossa, scaphoid fossa, concha cymba, concha cavum, and lobule (*Figure 1*).

The extrinsic muscles of the auricle are the anterior, superior, and posterior auricular muscles. The auricle is supplied by branches of the external carotid artery, including the superficial temporal and postauricular arteries (*Figure 2*).

The auricle is innervated by the great auricular nerve, auriculotemporal nerve (V3), lesser occipital nerve, and greater branch of the vagus nerve (Arnold's nerve) (*Figure 3*).

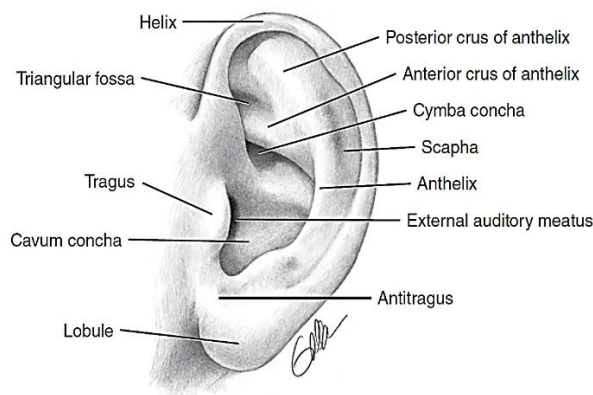


Figure 1: Anatomy of the auricle

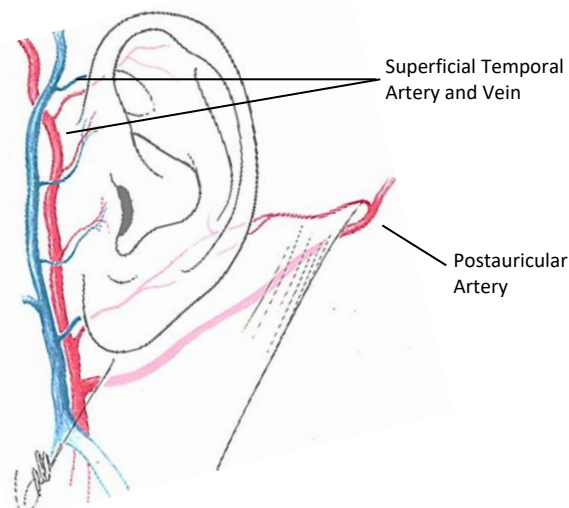


Figure 2: Blood supply of the auricle

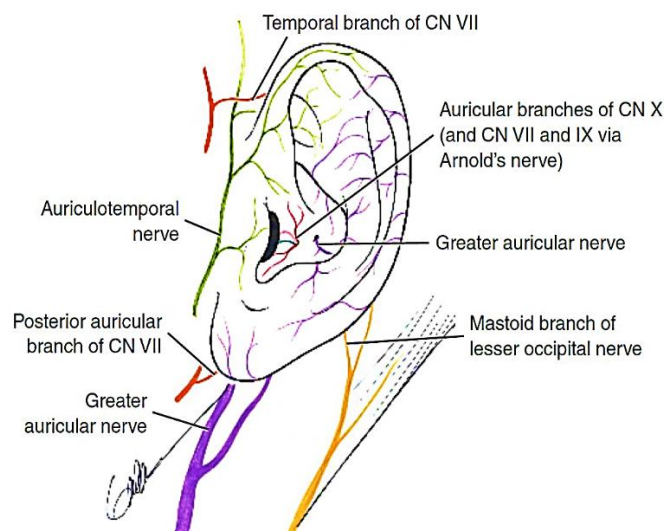


Figure 3: Nerve supply of the auricle

The vertical height of the ear is 5-6cm and should approximately match the distance between the orbital rim and the helical root. The width is approximately 55% of the vertical length. The vertical axis of the ear is inclined 15-20° posteriorly (Figure 4).

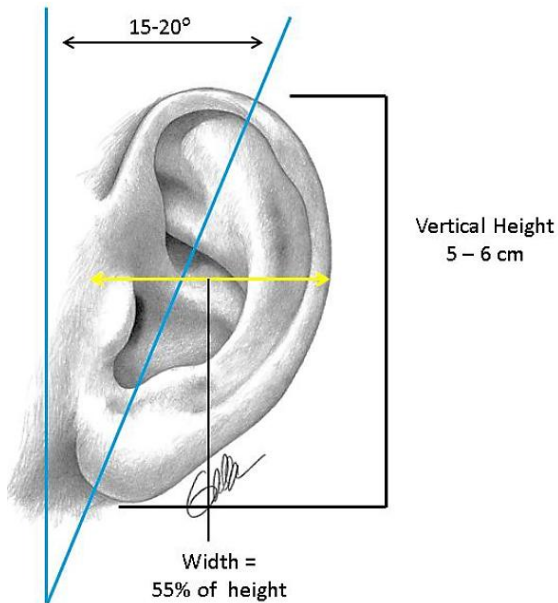


Figure 4: The vertical height of the ear is 5-6cm. The width is approximately 55% of the vertical length. The vertical axis of the ear is inclined 15-20° posteriorly

The superior-most point of the ear should be at the same level as the lateral eyebrow, and the inferior part of the lobule should be level with the subnasale (Figure 5).

The auriculocephalic angle, defined as the protrusion of the auricle from the scalp, should range between 25-35° (Figure 6).

To assess auricular protrusion, measurements are made at the most superior aspect of the rim, the most lateral projection point in the mid-auricle, and at a point at the level of the inferior helical rim. The average measurements for these points range from 10-12mm superiorly, 16-18mm at the middle point, and 20-22mm at the most inferior point.

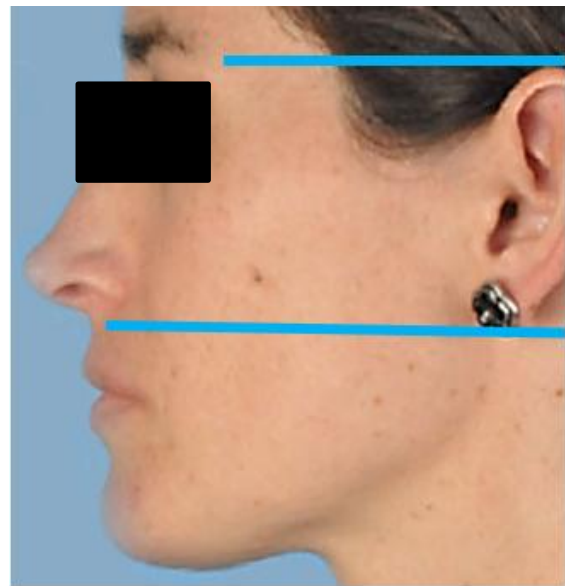

Figure 5: The superior most point of the ear should be at the same level as the lateral eyebrow, and the inferior part of the lobule should be level with the subnasale

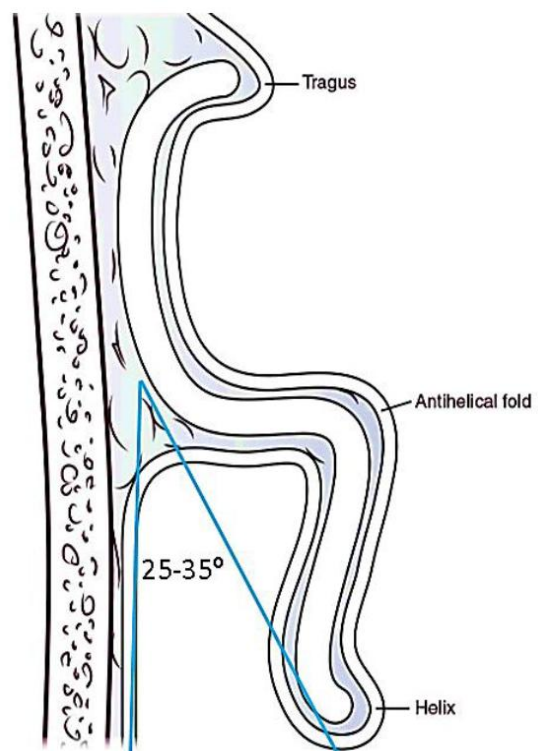


Figure 6: The auriculocephalic angle, defined as the protrusion of the auricle from the scalp, should range between 25-35°

Goals of surgery

The primary goal of otoplasty is to achieve a natural, symmetric, and aesthetic auricle. The specific surgical goals of otoplasty were summarised by Litner *et al*⁴

- Correction of precise anatomic defects
- Alignment of superior and inferior poles with the concha
- Establishment of appropriate auriculocephalic angles
- Preserving position of the helical rim lateral to the antihelix
- Maintaining the postauricular sulcus
- Maintaining interaural symmetry within 3 mm
- Ensuring that surfaces are smooth and without visible scars

Timing of otoplasty

Most surgeons prefer to wait until patients are at least 5 years of age, as the auricle is then 90-95% of adult size. Performing otoplasty on young children has the important advantage of minimising the social implications of the deformity. Additionally, the cartilage in children is more pliable, and ear deformities may be corrected more easily by cartilage-sparing methods.

Evaluation

A thorough preoperative evaluation includes examining ear symmetry, size, shape, and projection. Evaluation also includes documenting specific anatomic abnormalities. The two most common auricular defects are underdevelopment of the antihelix and increased projection of the conchal bowl. These defects may occur separately or simultaneously (*Figure 7*).

Anaesthesia

The authors prefer doing the surgery under local anaesthesia for adolescents and adults

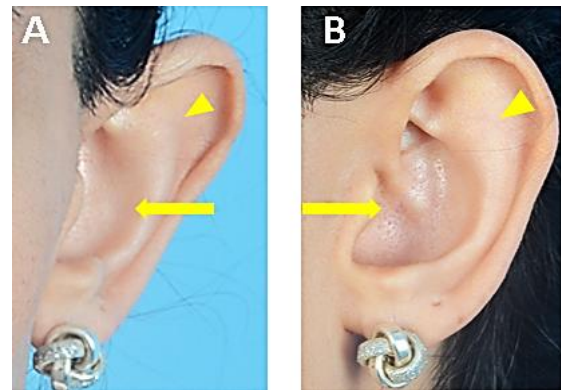


Figure 7: Frontal (A) and lateral (B) photographs of a prominent ear demonstrating both underdevelopment of the antihelix (arrowhead) and increased projection of the conchal bowl (arrow)

using 1% lidocaine with 1:100,000 epinephrine. General anaesthesia is commonly required for children.

Surgical technique

Hundreds of techniques have been described for correction of prominent ears. They can be classified into **2 broad categories i.e. cartilage-cutting and cartilage-sparing operations**.

Cartilage-cutting techniques include incisions, excisions, scoring, and/or abrasion of cartilage. The main advantage of cutting techniques is longterm stability of results. Disadvantages include disruption of cartilaginous support and creation of contour irregularities.

Cartilage-sparing methods were developed to reduce the incidence of contour irregularities and to maintain the structural support of the cartilage; however, longevity of results may be reduced when compared to cutting techniques.

Modern otoplasty favours a graduated approach by combining suture techniques, and, when appropriate, adding cartilage-cutting methods in a stepwise fashion until the desired correction is achieved.^{4,5}

Surgical steps

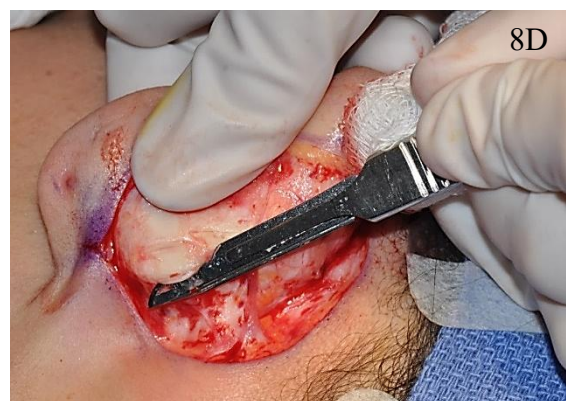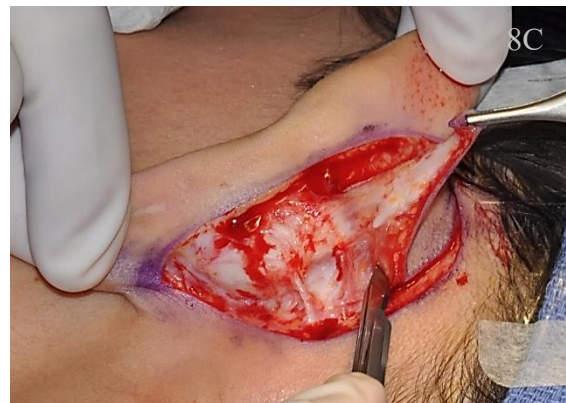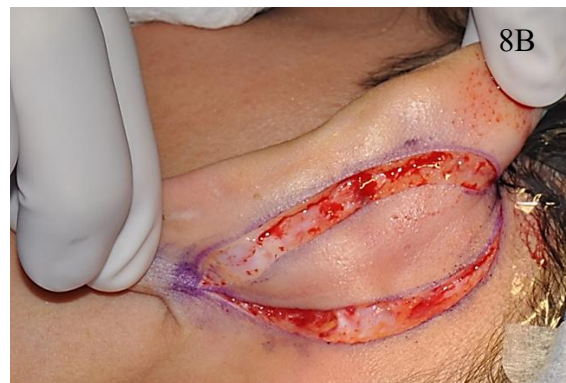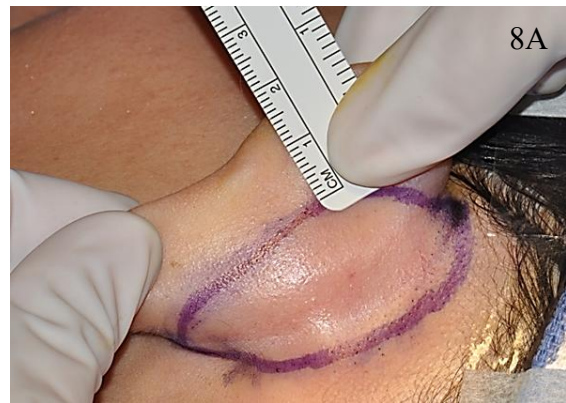The authors most commonly use a combination of Mustarde sutures⁶ for shaping of the antihelix, and Furnas sutures⁷ for conchal setback. Cartilage shaving is performed when appropriate to reduce projection of the conchal bowl.

Excising skin and soft tissue

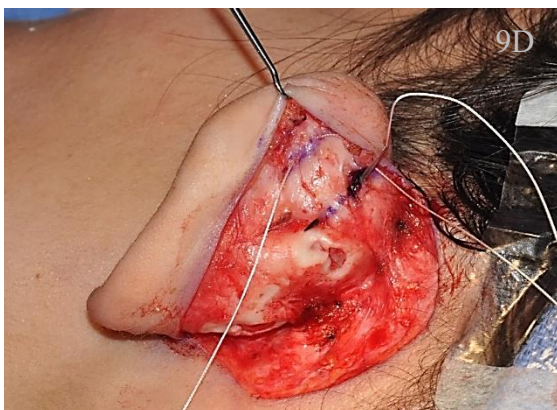
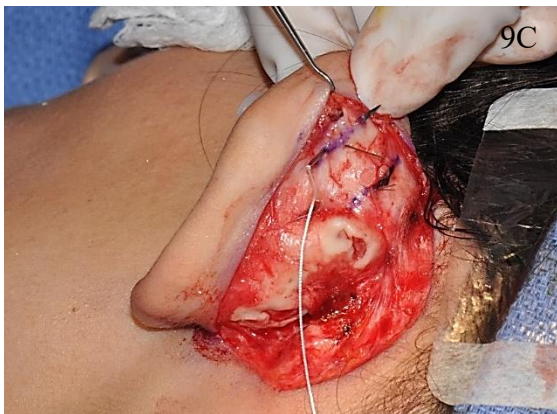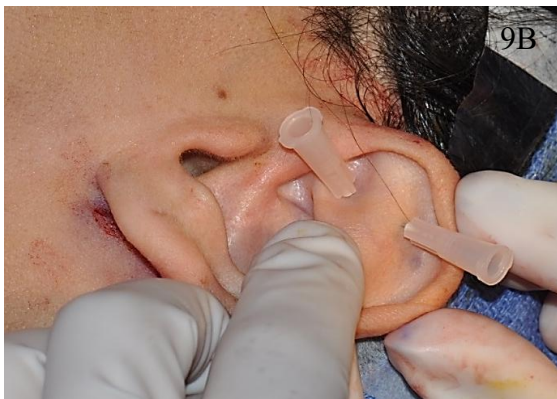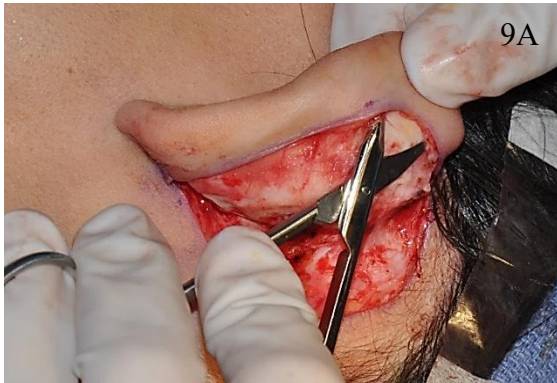- A fusiform excision is marked based on the postauricular sulcus, preserving 1.5 cm of free auricle (*Figure 8A*)
- Inject the area with 1% lidocaine with 1:100,000 epinephrine
- Use a 15 blade to make the planned incision (*Figure 8B*), and sharply excise the skin and soft tissue off the posterior cartilaginous framework (*Figure 8C*)
- In patients with a deep conchal bowl, elliptical shave excision of cartilage is performed with a 15 blade until the ear can be rotated to the proper position (*Figure 8D*)

Antihelix formation with Mustarde sutures

- Undermine the skin posteriorly over the free edge of the auricle to expose the area for placement of the Mustarde sutures (*Figure 9A*)
- Apply pressure to the ear to determine the appropriate position of the antihelical fold. Mark this position with two 30-gauge needles (*Figure 9B*)
- To recreate the antihelical fold, place two to three non-absorbable horizontal mattress sutures through the posterior perichondrium, cartilage, and anterior perichondrium, avoiding the anterior skin, and ligate them (*Figures 9C, D*)



Figures 8A-D: Excising skin and soft tissue



Conchal setback

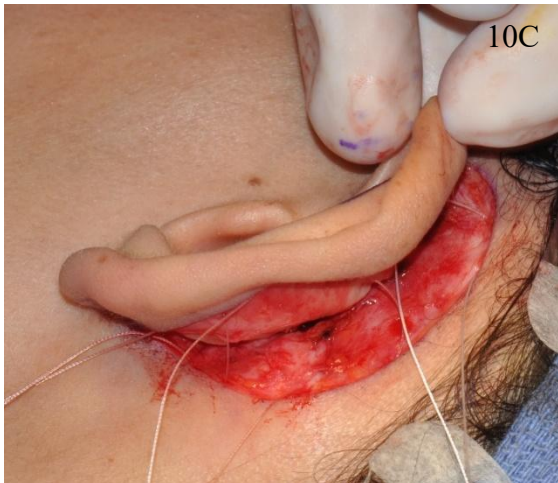
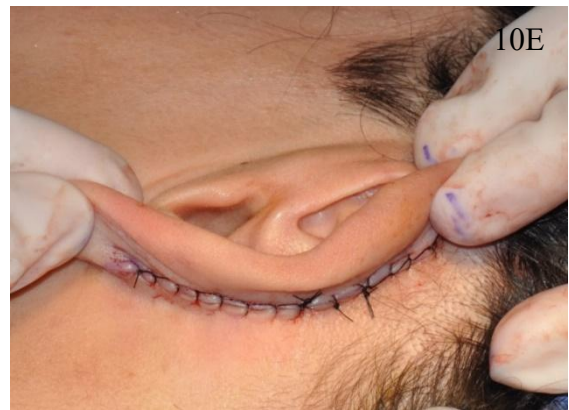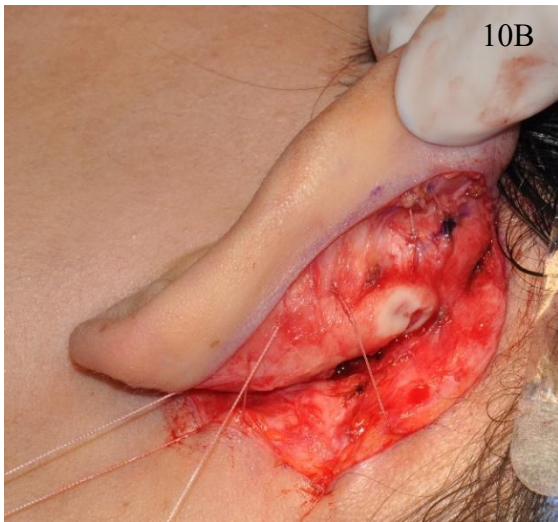
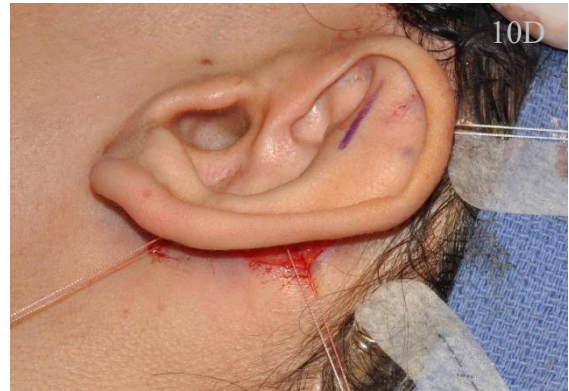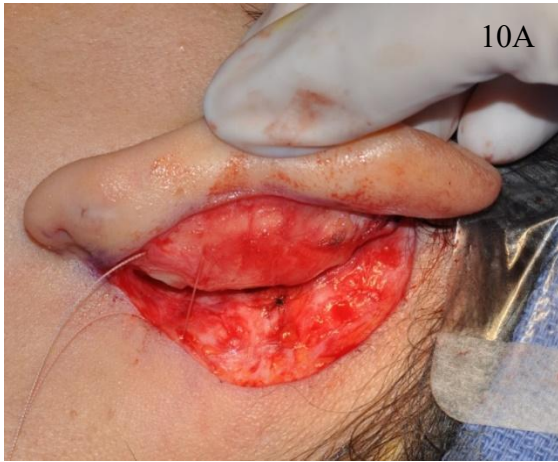
- Place three non-absorbable horizontal mattress sutures in a parallel fashion from the concha to the mastoid periosteum. These sutures are passed through the posterior perichondrium, cartilage, and anterior perichondrium, but do not go through skin
- The sutures are not secured until all sutures are in place
- The first suture is placed from the *concha cyma* to the mastoid periosteum (*Figure 10A*)
- The second suture passes between the *concha cavum* and the mastoid periosteum (*Figure 10B*)
- The superior suture is placed in the floor of the *fossa triangularis*, pulling the concha posteriorly and medially (*Figures 10C, D*)
- Close the incision with a running 4-0 black nylon suture, taking care not to disrupt the conchal setback sutures (*Figure 10E*)

Cartilage-cutting techniques^{8,9} (*Figure 11*)

Multiple cartilage-cutting techniques have been described and may involve scoring, cutting, and abrasion of cartilage. The cartilage-cutting technique described by Farrior⁸ is as follows:

- Place an incision immediately lateral to the site of the new antihelix
- Elevate the anterior skin
- Remove wedges of cartilage along the axis of the antihelix from the posterior aspect of the neo-antihelix
- Tube the antihelix anteriorly and place mattress sutures

Figures 9A-D: Antihelix Formation with Mustarde Sutures



Figures 10A-E: Conchal Setback

Treatment of protuberant lobule or lobule excess

- A protuberant lobule may be addressed by trimming the *cauda helicis*
- For lobule excess, the posterior auricular incision from the initial otoplasty is extended inferiorly and a small triangle of posterior skin is excised
- A small wedge of anterior skin is also excised
- The skin is closed with 6-0 nylon interrupted sutures

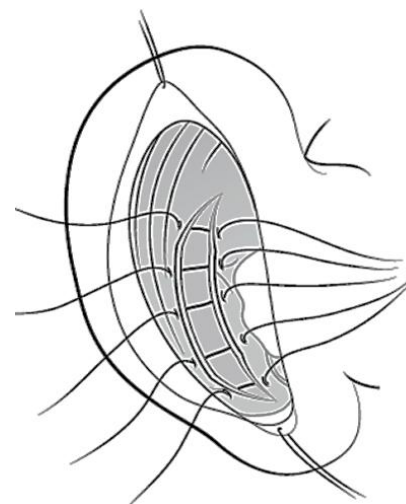
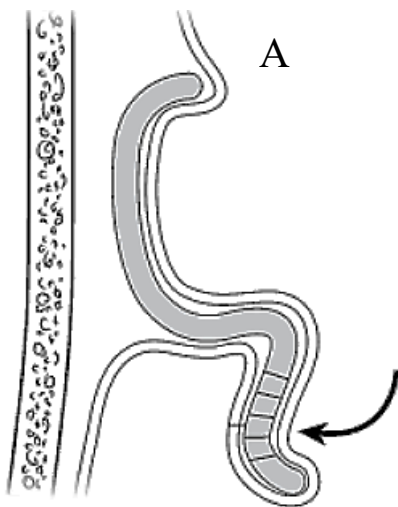
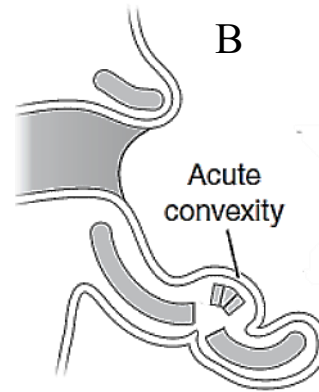
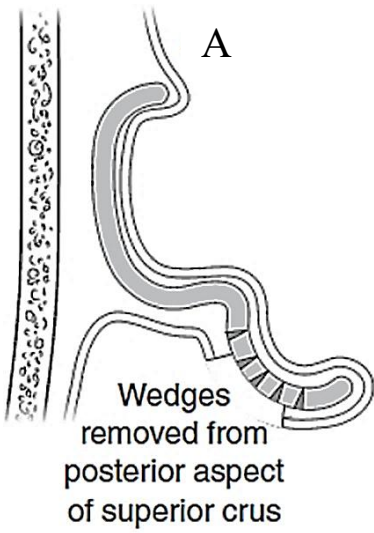
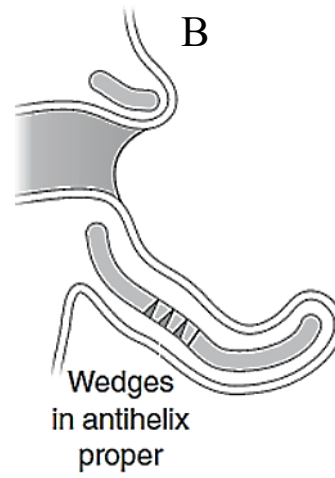
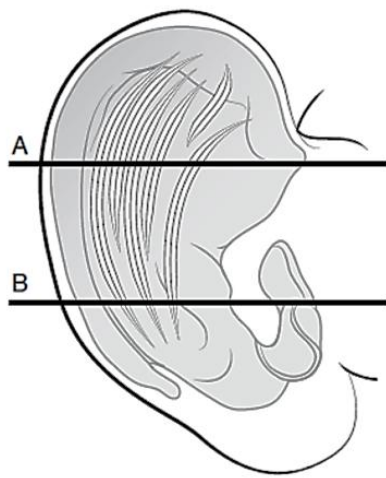


Figure 11: Cartilage cutting technique. A. At level of superior crus; B. At level of antihelix proper

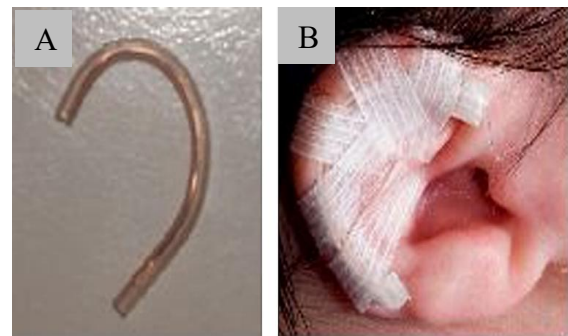
Postoperative care

- Apply Bacitracin ointment to the suture line, and dress the incision with non-stick gauze pads
- Wrap the head with an elastic bandage
- Discharge the patient home on 1 week of oral antibiotics and analgesia
- Instruct the patient to wear the bandage for the first 24 hours
- Thereafter the patient may shower and gently wash the hair
- A cotton headband is then placed; the headband is worn continuously until the postoperative appointment on Day 12
- During this visit, sutures are removed
- Instruct the patient to wear the headband at night for an additional 2 weeks

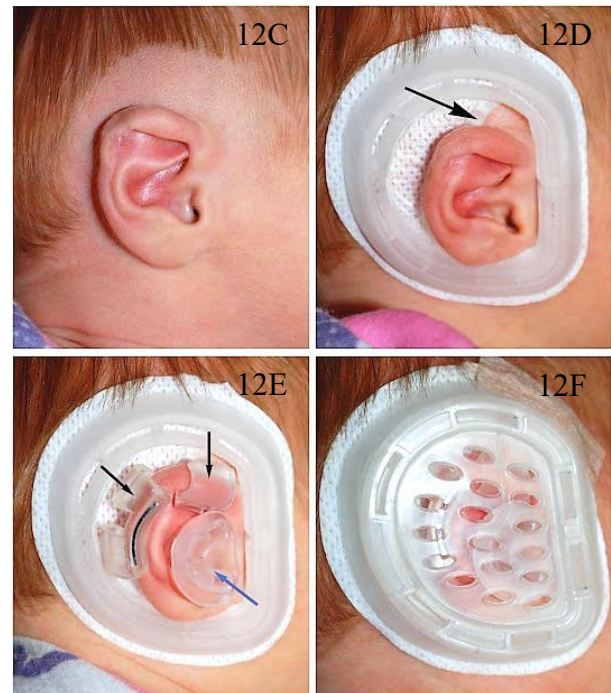
Non-surgical techniques: Ear splinting and moulding

Congenital auricular deformities, including prominent ears, are amenable to correction with splinting and moulding, especially when initiated within the first three days of life.¹⁰⁻¹² A variety of materials have been successful¹¹ including:

- Splints made from 6-Fr or 8-Fr silicone tubing with a 24 gauge copper wire core, applied with Steri-Strips^{10,12} (Figures 12A, B)
- Commercially available moulding devices, include the *Earwell Infant Correction System*TM (Figures 12C-F)
- The splint or mould remains in place 24 hrs/day and is replaced as necessary
- The duration of splinting varies from center-to-center, most commonly between 2-12 weeks
- Inspect the ear weekly for skin irritation and breakdown
- Fair-to-good results have been reported in 70-100% of patients, with better results in younger patients.¹¹



Figures 12 A, B: A: Splint made from 6-Fr silicone feeding tube with 24-gauge copper wire core; B: Splint applied to the newborn ear with Steri-Strips



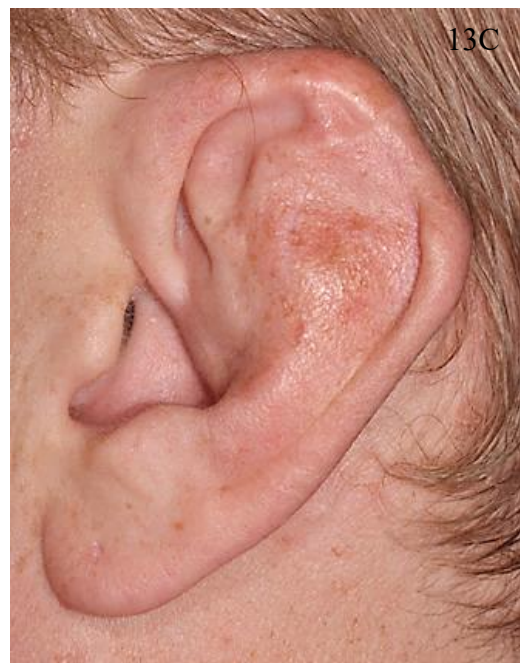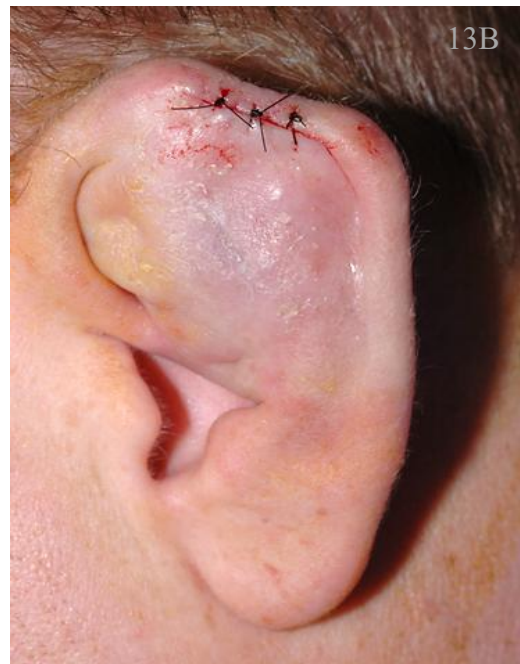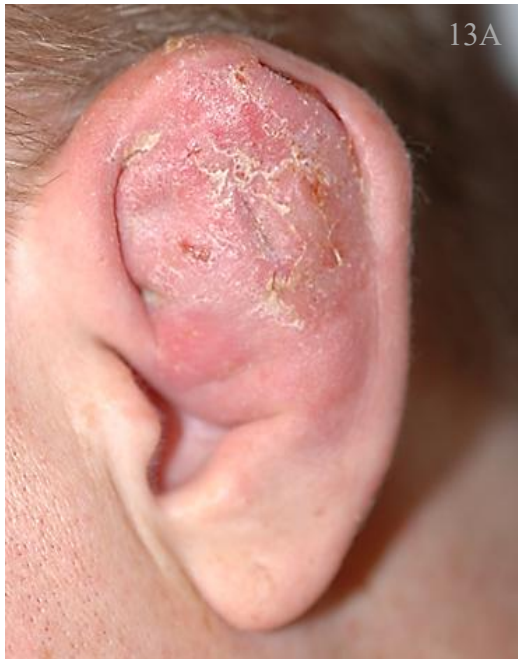Figures 12 C-F: Nonsurgical techniques. Commercially available *Earwell Infant Correction System*TM (Beacon Medical, Naperville IL)

Complications

Complications may occur early, within hours to days after the procedure, or late, occurring weeks to years later.^{5,13,14}

Early complications

- **Haematoma:** Haematomas occur in up to 3.5% of cases.¹⁴ Meticulous haemostasis should be achieved at the close of the procedure to minimise the risk of haematomas. Haematomas typically present with excessive asymmetric pain, blood-soaked dressings, bruising, or swelling. Urgent evacuation of a haematoma (*Figures 13A-C*) is critical to prevent fibrosis and ultimately, permanent deformity of the auricle, known as a “cauliflower ear” (*Figure 14*). Ensure careful haemostasis after evacuating a haematoma and place a drain and a pressure dressing. Discharge the patient on oral antibiotics and follow the patient closely until the haematoma has completely resolved.



Figures 13 A-C: A. Postoperative auricular haematoma; note fullness and discolouration of the auricle; B. Following incision and drainage; C. Final result

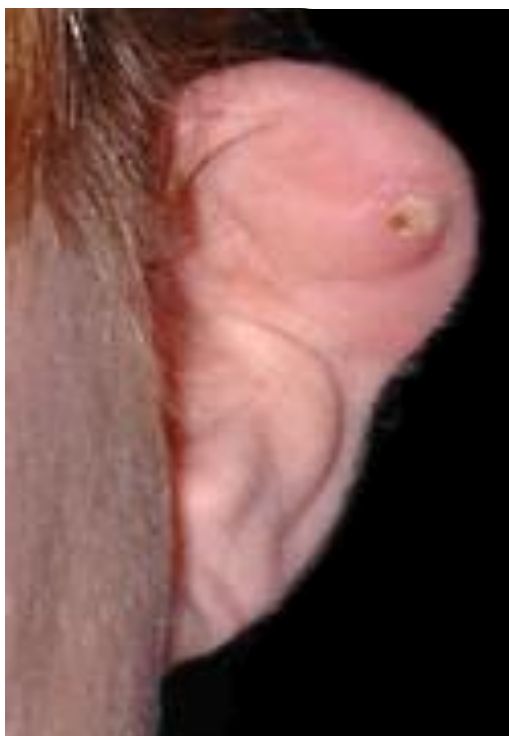

Figure 14: Cauliflower ear deformity following unevacuated haematoma

- **Infection:** Wound infection occurs in < 5% of otoplasties.¹³ As with haematomas, prompt identification and treatment are essential to avoid permanent deformity. Infections may present with pain, erythema, swelling, and drainage. Management includes drainage and irrigation of the wound, followed by treatment with oral anti-pseudomonas antibiotics. Patients with severe infection may require IV antibiotics.

Late complications

- **Loss of correction or relapse of auricular deformity:** This occurs more commonly after cartilage-sparing techniques. There are multiple technical causes of inadequate correction, including pulling of sutures over time, improper placement of sutures, failure to correct deformity during surgery, failure to anchor sutures firmly on the mastoid periosteum, or failure to weaken

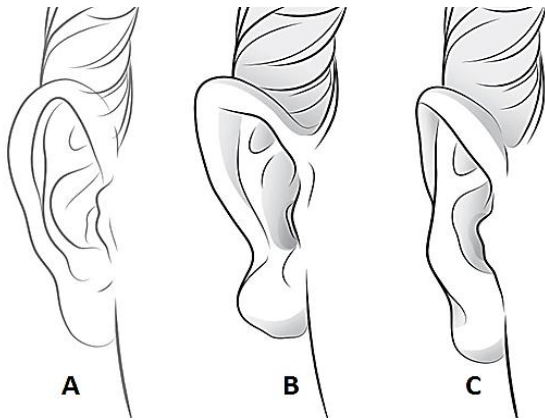
noncompliant cartilage. Inadequate correction requires revision otoplasty.

- **Suture-related complications:** Non-absorbable sutures may extrude or cause foreign body reactions. Braided sutures cause more reactions as compared to monofilament sutures; however, many prefer braided sutures due to their handling properties. In cases of inflammatory reaction or extrusion, removal of the suture resolves the complication, though the final result may be compromised
- **Hypertrophic scarring and keloid:** The postauricular area may develop hypertrophic scars or keloid (Figure 15), especially in patients with darker skins, younger patients, or patients with a history of hypertrophic scarring or keloid. In susceptible patients one should avoid unnecessary tissue trauma and ensure a tension-free closure. Treatment of hypertrophic scarring and keloids includes triamcinolone injections every 4 - 6 weeks for 6 months.¹⁴

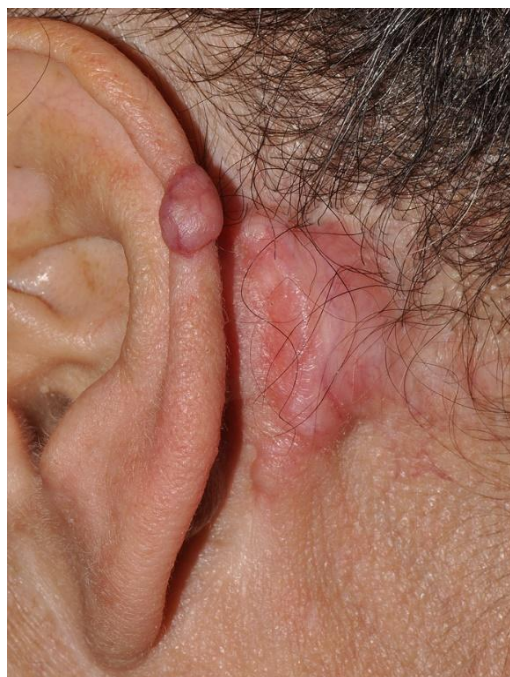

Figure 15: Postauricular keloid

- **Telephone and reverse telephone ear deformities:** Telephone ear deformity occurs with overcorrection in the middle third of the ear and relative undercorrection of the superior and inferior poles (Figures 16A, B). Reverse telephone ear deformity occurs when the middle third of the auricle remains prominent relative to the superior and inferior poles (Figure 16C). Both deformities are avoidable with correct placement of the conchal setback sutures.



Figures 16 A-C: Normal anatomy (A), telephone ear deformity (B), and reverse telephone ear deformity (C)

- **Narrowing of external auditory canal:** This may be seen after conchal setback with improperly placed sutures. When placing Furnas conchal setback sutures, care must be taken to pull the concha superomedially to avoid canal narrowing.

References

1. Weerda. *Surgery of the Auricle: Tumors, Trauma, Defects, and Abnormalities*. 1st ed. New York: Thieme; 2007
2. Macgregor FC. Ear deformities: social and psychological implications. *Clin Plast Surg*. Jul 1978;5(3):347-50
3. Bradbury ET, Hewison J, Timmons MJ. Psychological and social outcome of prominent ear correction in children. *Br J Plast Surg*. Feb-Mar 1992; 45(2):97-100
4. Adamson PA, Litner JA. Otoplasty technique. *Otolaryngol Clin North Am*. Apr 2007;40(2):305-18
5. Petersson RS, Friedman O. Current trends in otoplasty. *Curr Opin Otolaryngol Head Neck Surg*. Aug 2008; 16(4):352-8
6. Mustarde JC. The correction of prominent ears using simple mattress sutures. *Br J Plast Surg*. Apr 1963;16:170-8
7. Furnas DW. Correction of prominent ears by conchamastoid sutures. *Plast Reconstr Surg*. Sep 1968;42(3):189-93
8. Farrior RT. Modified cartilage incisions in otoplasty. *Facial Plast Surg*. 1985;2:109-18
9. Manz RW, B. Otoplasty: Surgical Correction of the Prominent Ear. In: Cheney MH, T.A., ed. *Facial Surgery, Plastic and Reconstructive*: CRC Press; 2014
10. Petersson RS, Recker CA, Martin JR, Driscoll CL, Friedman O. Identification of congenital auricular deformities during newborn hearing screening allows for non-surgical correction: a Mayo Clinic pilot study. *Int J Pediatr Otorhinolaryngol*. Oct 2012;76(10): 1406-12
11. van Wijk MP, Breugem CC, Kon M. Non-surgical correction of congenital deformities of the auricle: a systematic review of the literature. *J Plast Reconstr Aesthet Surg*. Jun 2009;62 (6): 727-36
12. Tan ST, Shibu M, Gault DT. A splint for correction of congenital ear deformities. *Br J Plast Surg*. Dec 1994;47 (8):575-8
13. Adamson PA, Litner JA. Otoplasty technique. *Facial Plast Surg Clin North Am*. May 2006;14(2):79-87, v
14. Owsley TG, Biggerstaff TG. Otoplasty complications. *Oral Maxillofac Surg*

Clin North Am. Feb 2009;21(1):105-18, vii

How to cite this chapter

Banks CA, Cheney M. (2015). Otoplasty surgical technique. In *The Open Access Atlas of Otolaryngology, Head & Neck Operative Surgery*. Retrieved from <https://vula.uct.ac.za/access/content/group/ba5fb1bd-be95-48e5-81be-586fbaeba29d/Otoplasty%20surgical%20technique.pdf>

Authors

Caroline A. Banks, M.D.
Clinical Fellow
Division of Facial Plastic and Reconstructive Surgery
Department of Otolaryngology/Head and Neck Surgery
Harvard Medical School/Massachusetts Eye and Ear Infirmary
Boston, Massachusetts, USA
Caroline_Banks@meei.harvard.edu

Mack Cheney, M.D.
Director
Office of Global Surgery and Health
Division of Facial Plastic and Reconstructive Surgery
Department of Otolaryngology/Head and Neck Surgery
Harvard Medical School
Massachusetts Eye and Ear Infirmary
Boston, Massachusetts, USA
Mack_Cheney@meei.harvard.edu

Editor

Johan Fagan MBChB, FCS (ORL), MMed
Emeritus Professor and Past Chair
Division of Otolaryngology
University of Cape Town
Cape Town, South Africa
johannes.fagan@uct.ac.za

THE OPEN ACCESS ATLAS OF OTOLARYNGOLOGY, HEAD & NECK OPERATIVE SURGERY

www.entdev.uct.ac.za



The Open Access Atlas of Otolaryngology, Head & Neck Operative Surgery by [Johan Fagan \(Editor\) johannes.fagan@uct.ac.za](mailto:johannes.fagan@uct.ac.za) is licensed under a [Creative Commons Attribution - Non-Commercial 3.0 Unported License](https://creativecommons.org/licenses/by-nc/3.0/)

