

OPEN ACCESS ATLAS OF OTOLARYNGOLOGY, HEAD & NECK OPERATIVE SURGERY



OTOLOGY OUTREACH SURGERY IN DEVELOPING COUNTRIES UNDER LOCAL & REGIONAL ANAESTHESIA: TECHNIQUES & PITFALLS

Richard Wagner, Greg Torr

This chapter describes some techniques to safely perform middle ear and mastoid surgery in outreach ear surgery programs and discusses tips and pitfalls. It should be read in conjunction with the chapter: [Local and regional anaesthesia techniques for otologic \(ear\) surgery](#) which provides a more detailed account of local anaesthesia technique for ear surgery.

When surgeons travel to developing countries to do outreach ear surgery, they often lack the convenience of having a qualified anaesthetist, trained recovery room staff, adequate monitoring equipment for safe general anaesthesia, and are faced with long lines of patients requiring ear surgery. It is under such circumstances that ear surgery is ideally done under local or regional anaesthesia.

Performing otology procedures under local, as opposed to general anaesthesia has many advantages and can be described as “God’s Gift to Otology”. It allows one to perform middle ear surgery and monitor vestibulo-cochlear function without expensive (and often unavailable) equipment, along with reducing risks associated with general anaesthesia.

It is critical that the surgeon has both the level of experience and comfort to perform middle ear surgery under local anaesthesia with sedation. Although rather rare (<1% of cases), situations do arise when even an experienced surgeon must abandon an operation or convert from local to general anaesthesia to complete the surgery.

Even qualified anaesthetists may lack experience with using only a limited range of drugs to provide IV sedation. Under such circumstances it may be important that the

surgeon assist the anaesthetist to select the appropriate drugs that will provide sufficient hours of analgesia and sedation.

Caveat: Intravenous sedation can be a dangerous practice if performed without adequate monitoring or if the sedation practitioner is unfamiliar with the agents presented to him/her.

Rationale of ear surgery under local anaesthesia with sedation

Safety: Patient safety is the priority when performing surgery. Safety of properly administered local anaesthesia with intravenous sedation is well established *providing that the attending surgeon has both the experience and confidence in the practice of local/regional anaesthesia and sedation.*

Reliability: Provided that patients are selected according to the criteria listed below and reliable drugs are administered, the methods described provide a reliable alternative to general anaesthesia in >90% of cases.

Anaesthetic technique and safety: In developing countries there is a greater risk of anaesthetic-related complications or deaths due to frequent use of non-physicians to administer anaesthesia, inadequate monitoring equipment, and unreliable drugs. It is the surgeon’s responsibility to manage the operating theatre and to lead the surgical team, which includes communicating with the anaesthetist and agreeing on drugs to use to achieve adequate levels of anaesthesia for sufficient duration.

Comorbidities: Unrecognised and untreated comorbidities can cause complications and even deaths. In patients with known comor-

bidities, local anaesthesia with sedation is a safer technique to employ.

Shorter recovery room time: Patients are essentially awake immediately after the surgery and go to the recovery room for observation to ensure that there is no rebound respiratory compromise and that vital signs are stable. Intravenous sedation therefore requires a shorter recovery room time than general anaesthesia and patients are generally ready for discharge after being observed for 30 minutes.

Intraoperative monitoring of vestibular, cochlear and facial nerve function: A patient in a semiconscious state can respond to questions during surgery; hence the surgeon can assess the ossicular chain reconstruction intraoperatively. With stapes surgery, vestibular function can be ascertained and errors such as inserting a too long piston can be avoided. While removing bone from the facial ridge during canal wall down mastoidectomy, the facial nerve can be monitored by watching the face and by asking the patient to smile or open the eyes.

The Patient

Not all patients are suited to ear surgery under local anaesthesia with IV sedation.

Age: Patients should be at least 18yrs old to understand the concept of undergoing ear surgery while awake. Younger children tend to be too anxious and are less understanding. Older patients can cause problems as sedative drugs dosages need adjustment and a cautious titrated approach is advised to avoid excessive sedation.

Prior surgery: Patients who have had prior ear surgery frequently do not tolerate revision surgery under local anaesthesia. This may be because fibrosis and scarring inhibit delivery of lidocaine to the surgical field to ensure adequate anaesthesia.

Mental status: Very fearful or anxious patients, or those with underlying mental conditions are not considered ideal candidates.

Counselling and consent

Once a patient has been counselled about risks, benefits and surgical options, then administration of anaesthesia is discussed. The surgeon counsels the patient about the diminished risks of local anaesthesia compared to general anaesthesia, and the benefits in terms of being able to monitor cochleovestibular function during surgery and to optimise hearing outcome.

Fasting

The patient should be starved for a minimum of 6 hours (adults) prior to surgery, even if general anaesthesia is not anticipated.

Monitoring during middle ear surgery

Patients receiving IV sedation and local anaesthesia for middle ear surgery need to be carefully monitored. A pulse oximeter, ECG machine, and blood pressure monitor need to be used. However, in developing countries there is often not a functioning anaesthetic machine, there may not be inhalational agents or monitoring equipment, trained anaesthetists or nurse anaesthetists.

Pulse oximetry: Pulse oximetry is critical to monitor blood oxygen saturation. Oxygen saturation should be maintained at 90-100%. When supplemental oxygen is not available, careful monitoring is even more critical to avoid oversedation, depressed breathing, hypoxia and hypercarbia. One may even have to assist ventilation with an Ambu bag. Treatment of low oxygen saturations with supplemental oxygen is only a shortterm solution and can mask a greater problem: hypoventilation and hypercarbia.

If it is possible, rather communicate with the patient and encourage deep breathing.

Blood pressure: Hypertensive patients require medication to make them normotensive. It occurs more commonly with patients who have undiagnosed hypertension and should be detected during preoperative medical screening. Hypertension can be severely exacerbated by systemic absorption of adrenaline/epinephrine in the dental cartridges of Lignocaine/Lidocaine. In such cases consideration might have to be given to using local anaesthetic without adrenaline/epinephrine, or to postpone surgery until the patient is normotensive.

ECG monitoring: The pulse and ECG tracing may reveal tachycardia following injection of epinephrine. The tachycardia is usually short-lived and generally settles after 3-5 minutes. Alternatively, a gentle massage of the carotid artery may help. Rarely can a short-acting beta-blocker be administered.

Resuscitation equipment

Resuscitation equipment in the event of an adverse reaction to local anaesthetics, sedatives and/or antibiotics must not only be present and in working order, but the practitioner needs to familiarise him/her with their use and function. Equipment includes a powerful suction machine and airway suction device *e.g.* Yankauer sucker, a functioning laryngoscope (and spare bulbs and batteries), endotracheal tubes of appropriate sizes, and an Ambu bag.

Drugs

Emergency drugs that must be available include Adrenaline/Epinephrine, Atropine, steroids and antihistamines.

Drugs are employed *to achieve analgesia* so that patients do not feel pain and to

achieve *sedation* so that they are less aware of the surgery and anxiety is minimal. One must plan to have the correct drugs available or adapt the anaesthetic technique to the drugs that are available.

Lidocaine (1% or 2%) is appropriate for local analgesia. Its analgesic effect lasts 2-4 hours (majority of middle ear surgeries take <2hrs). The 1st author uses 5-8ml of lidocaine & epinephrine in >98% of cases, which is well below the maximum adult dose of lidocaine of 7mg/kg.

Adrenaline (epinephrine) provides haemostasis and a dry surgical field. Half a ml (half an ampoule) of adrenaline 1:1000 is added to 9ml of lidocaine drawn up into a 10ml syringe to achieve a concentration of lidocaine:epinephrine of 1:30,000. It is well tolerated, although rarely a patient may develop tachycardia which usually subsides within <5 minutes.

Systemic analgesia *e.g.* Fentanyl, morphine sulphate, or Meperidine (Demerol) is administered intravenously in combination with the injection of lidocaine & epinephrine. **With all systemic analgesics it is imperative to monitor the patient's breathing and oxygen saturation.** The choice of intravenous analgesic often depends on its availability. Because the 1st author most frequently encounters fentanyl on his travels, it is his 1st line agent. For the average person weighing 130-150lbs (59-68kgs), he starts by titrating 50µg of fentanyl. A further 50 bolus can be given if the patient tolerates this well without hypoventilation. For patients with a body mass closer to 200 pounds (91kgs) he uses up to 125-150µg of fentanyl (titrated). In countries like American Samoa where the body mass index is of the highest in the world, it is not unusual to administer up to 300µg of Fentanyl. With Demerol, the author generally administers about 75mg for an average sized person; for morphine sulfate, he administers 7.5-10mg.

Benzodiazepines are used to reduce anxiety. The 1st author generally uses diazepam (valium) or *Midazolam* (*Versed*). He prefers diazepam because of its slower onset and longer action. Diazepam is, however, frequently not available, while *Midazolam* is generally available in developing countries. *Midazolam* has a much more rapid induction and shorter duration of action but has a higher risk of respiratory depression.

Note that a **combination of benzodiazepines and opioids can be additive** especially in patients that are drug/medication-naïve. Caution should be exercised when administering these medications and a titrated approach is advised, starting with smaller doses and working up to those stated above.

Reversal agents: It is strongly advised that the operator familiarizes him/herself with opioid and benzodiazepine reversal agents and their use and doses in the event of oversedation.

- **Naloxone:** 1 ampoule = 0.4mg. Dilute into 4ml with saline and titrate 1ml/0.1mg IVI every 2-3 minutes until the patient recovers consciousness and (airway) reflexes
- **Flumazenil:** Comes as a 0.1 mg/ml preparation. Dosage 0.2mg IVI titrated every 2 minutes until consciousness is regained
- **Overdosing** with either of these drugs can cause hypertension and severe pain

Microscopes

In many developing countries it is difficult to secure a functioning operating microscope. Frequently we find an old Zeiss microscope that uses an incandescent light bulb (*Figures 1, 2*). One should enquire what microscope is to be used and ensure that spare light bulbs are available or bring light bulbs along. Even though these microscopes work

well, the light intensity is poor when compared to new microscopes.

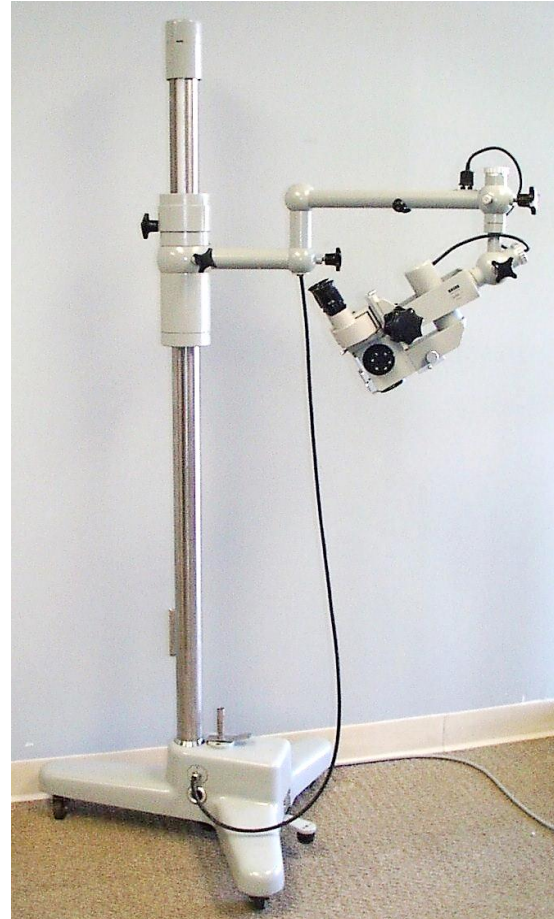


Figure 1: Older model Zeiss (OPMI-1) operating microscope with incandescent bulb



Figure 2: OPMI-1 incandescent light bulb

The objectives should be 10x power and a 250mm lens is preferred. A 300 or 200mm lens can also be used as long as one refocuses the eyepieces to their limits to adjust for the best depth of field. To provide live video for teaching one should take along a beam-splitter; video adapter; C-mount coupler; video camera, and appropriate video cables. The camera is attached to a computer monitor or TV depending on the output connection. (VGA, HDMI, DVI, S-video) (Figure 3). It is therefore important to contact your host to find out what monitors are available.

Endoscopic ear surgery

The author favours the microscope, but endoscopic surgical techniques may have advantages for middle ear surgery in outreach settings as the equipment is compact and portable. See chapter: [Endoscopic cholesteatoma, tympanoplasty and middle ear surgery](#). However, one requires a very cooperative patient as the head must be kept very still throughout the procedure to avoid the endoscope injuring the ear should the head suddenly move. It should also be noted that patients in developing countries usually have much more advanced ear disease because diagnoses are usually delayed. Therefore, especially in patients with cholesteatoma, a canal-wall-down modified or radical mastoidectomy is generally preferred and is performed easier with a microscope than with an otoscope.

Sterilising surgical instruments

Depending on what is available in the country one is visiting, instruments may be sterilised by a variety of methods *e.g.* autoclaving with steam vapour; or soaking instruments in alcohol, “cidex” or in acetone. Irrespective of the sterilisation technique, instruments should be rinsed in a sterile saline solution before use.

Operating room setup and positioning (Figure 3)

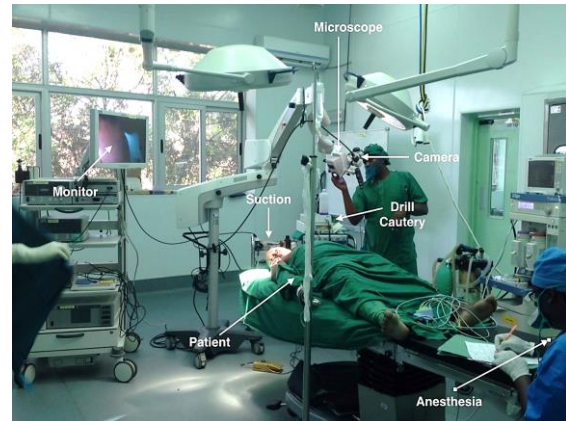


Figure 3: Operating room setup & camera system

Surgical equipment

Knife handle
Weitlaner self-retaining retractors (2)
Adson forceps w/teeth
Iris scissors curved
Iris scissors straight
Senn retractor
Joseph Skin Hook, 2 prong
Beckmann nasal speculum
Suction tips 10, 14, 18 ,20 F
House double-ended large spoon curette sizes 2 x 3.2mm & 1.6 x 2.6 mm
Freer elevator
Ear speculum 4, 5, 6, 7, 8mm
Bellucci scissors
Hartmann forceps
Malleus nipper
Cup forceps
Cutting block
Needle holder
Suture scissors
Round knife 2.5 & 1.0mm
Annulus elevator
Rosen pick
Fish rasp (right & left)
Sickle knife
45° pick

Table 1: List of ear instruments required

The instruments listed above are the 1st author's preference and are adequate to allow one to perform tympanoplasty, mastoidectomy, canalplasty, temporal bone resection, and other middle ear surgeries.

Audiology

It is imperative that all patients have an audiogram done before ear surgery. It should ideally be done by someone trained to test hearing, because an untrained tester will *e.g.* not understand how to mask the opposite ear and will therefore get erroneous results.

Surgical steps of middle ear surgery under local anaesthesia with sedation

A time window of 1-2 hours should be available to complete surgery when using 5-9ml of local anaesthetic solution and a titrated intravenous dose of up to 150ug of fentanyl or up to 10mg of morphine. If a patient requires more sedation or analgesia during surgery, either drug can be given depending on the need.

Induce IV analgesia and sedation

- Administer IV analgesia & sedation (Fentanyl & valium as described above)
- Wait for drugs to take effect (within 5 minutes)
- Assess that adequate sedation has been achieved by asking the patient to respond to simple questions or commands (*e.g.* "squeeze my hand")
- The patient should be rousable by speech or gentle touch
- Note: If the eyelid reflex is lost, the patient is too deeply sedated and is bordering on general anaesthesia!
- Proceed to inject the local anaesthesia

Auricular block

- Mix 0.5ml (half ampoule) of adrenaline 1:1000 and 9ml of lidocaine in a 10 ml syringe
- Use a 27-gauge needle (small gauge causes less pain and tissue trauma)
- Start injecting the local anaesthetic
- Note any pain reaction from the patient

Three sites are injected to achieve an adequate ear block

1. Postauricular injection

- Begin infiltrating at the level of the external auditory canal
- Slowly inject about 0.5ml of local anaesthetic to form a small blister under the skin (*Figure 4*)

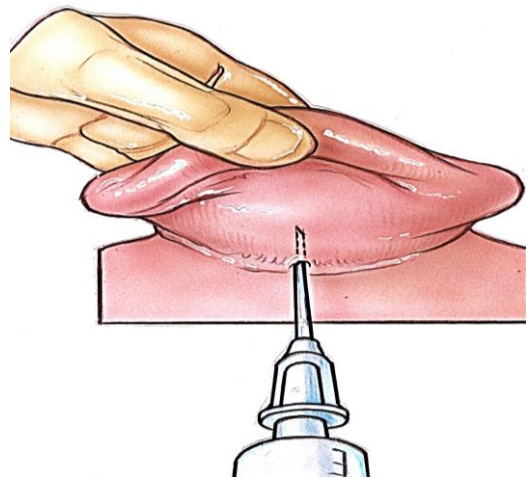


Figure 4: Begin infiltrating at level of external auditory canal

- Rotate the needle superiorly and advance it under the skin to the top of the helix
- Inject 2-3ml solution while slowly advancing the needle inferior to the site of the original blister; as this is done, the area of infiltration should puff up
- Using the initial injection site, insert the needle under the concha so that the tip is close to the external auditory canal skin at the level of the spine of Henle

- Infiltrate 1-1.5ml local anaesthetic in a radial fashion about 3 times (*Figure 5*)

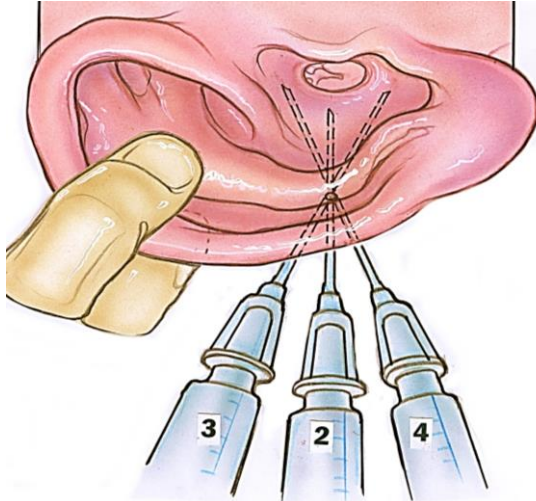


Figure 5: Infiltrate local anaesthetic in a radial fashion

2. *Intracanal injection* (*Figures 6a, b*)

- Insert the largest ear speculum that fits into the ear canal, and view the canal with the operating microscope
- Infiltrate the canal skin with 3 - 4 injections of solution; each injection is 0.25-0.40 ml
- Initiate the 1st injection at the junction of the medial 1/3 of the canal, and the lateral 2/3 at the 9 o'clock position where there is hair and subcutaneous tissue
- Commence the injection around the level of the most medial hair follicles
- Then advance the needle a few millimeters onto the bone with its bevel facing down before injecting
- As one infiltrates the local anaesthetic, blanching of the *stria vascularis* is seen
- Commence the 2nd injection at a 12 o'clock position
- Commence the 3rd injection at a 6 o'clock position
- The 6 and 12 o'clock injections provide anaesthesia for the canal incisions that are made when elevating the conchomeatal flap

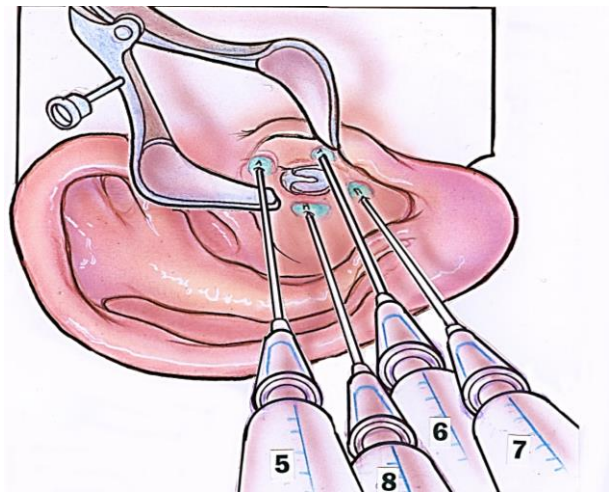


Figure 6a: Canal injection

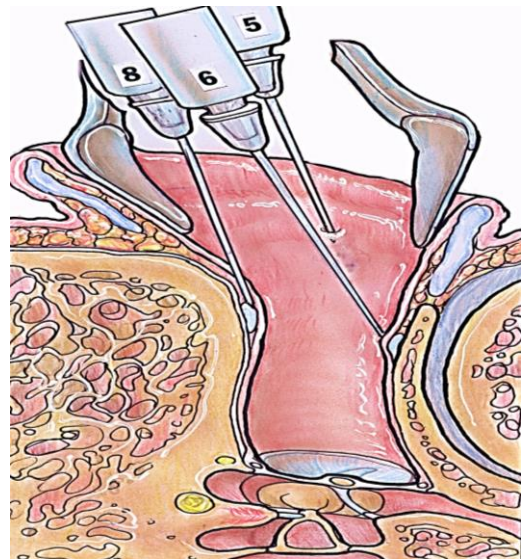


Figure 6b: Axial view of canal injection

3. *Preauricular injection* (*Figure 7*)

- This injection provides anaesthesia to the anterior canal which is supplied by the auriculotemporal division of the trigeminal nerve
- Insert the needle at a 45° angle in front of the tragus
- Advance the needle towards the angle of the mandible
- Commence infiltration after the needle has reached its maximum depth and inject 0.5-0.75ml solution as the needle is retracted

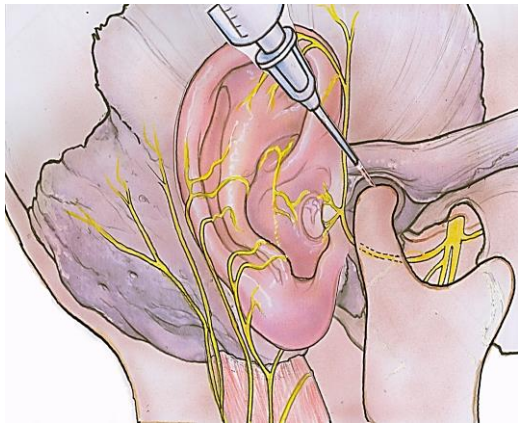


Figure 7: Preauricular injection to block the auriculotemporal nerve

Middle ear surgery technique

It is critical that a surgeon performing ear surgery has both the experience and comfort to perform middle ear surgery under local anaesthesia with IV sedation. Under ideal circumstances an experienced ear surgeon is able to perform tympanoplasty (underlay or overlay), stapes surgery, modified or radical mastoid surgery, lateral temporal bone resection, and even endolymphatic sac decompression under IV sedation and local anaesthesia.

Consumables checklist for outreach surgery

- 4/0 Monocryl sutures
- Gelfoam (Johnson & Johnson)
- Xeroform gauze
- Quinolone antibiotic solution
- Silastic sheeting – 1st author uses surgical gloves
- Kerlix gauze bandages (3 or 4”)
- Syringes
- Needles
- Lidocaine
- Adrenaline
- Systemic analgesic
- Analgesics for postoperative pain relief

Cleaning solutions

Microscope and audiovisual equipment: Check for available microscope and spare bulbs

ENT clinic equipment

- Tuning forks
- Jobson-Horne
- Otoscopes
- Suture scissors
- Etc.

Ear surgery instrumentation

Pearls & Pitfalls

1. Critical to carefully select patients
2. Preoperative audiogram imperative unless impossible to obtain
3. Important to monitor patients during surgery with ECG, oximeter, and blood pressure monitor
4. More important is a human monitor. If a qualified anaesthetist is not available, then either the surgeon or a trusted nurse must watch the patient and monitor and encourage deep breathing when needed
5. Inject atraumatically using the smallest needle possible, but no smaller than a 27-gauge, keeping the bevel facing down
6. Ensure that the drugs to be use are not fake or adulterated; The 1st author has frequently encountered such medications in developing countries that do not function properly
7. When you notice a patient becoming more awake, notify the anaesthetist
8. If the patient experiences pain while operating in the middle ear, irrigate the middle ear down the canal with 2ml of 1-2% lidocaine without epinephrine, leaving it in the middle ear for 2min before suctioning it out
9. If mucosal bleeding from the middle ear persists, irrigate the middle ear with 2ml pure epinephrine down the canal and

- leave it there for 2 minutes before suctioning it from the middle ear cleft
10. Be prepared to handle any and all complications you may encounter, such as repairing a CSF leak, and repairing the facial nerve if injured
 11. Power failures are common in some countries, especially in rural settings, and should be anticipated. If a drill stops functioning or power fails after a mastoidectomy has been commenced, then the surgeon may have to resort to a hammer and gouge technique to complete the surgery: See chapters: [Hammer and gouge for cholesteatoma](#); [Hammer and gouge for acute mastoiditis](#)

Pointers for teams planning outreach surgery in resource limited countries

When the 1st author works in developing countries, visits are coordinated through an NGO, a local doctor or through a medical society. Irrespective of who is the host, it is imperative that the following rules be followed:

1. The primary goal is to share knowledge and skills by teaching local doctors about ear disease and surgery
2. Arrange for local doctors to schedule patients and manage follow up
3. If there is no local ENT doctor to participate in the program, it is imperative that one identifies another doctor to take responsibility for postoperative care, also using telemedicine for advice
4. In the absence of a microscope, one may be required to bring along a portable operating microscope
5. In the absence of a locally based microscope it is impossible for the local doctor to do microscopic postoperative ear care. In such cases the surgery must be tailored in such way to make it possible for the local doctor to manage ears post-operatively without a microscope:

- With tympanoplasty, pack the ear canal with resorbable *Gelfoam*; with a modified meatoplasty, place gauze e.g. *Xeroform* in the lateral canal and instruct the doctor to remove the gauze at 10 - 12 days and then begin placing Ciprofloxacin eardrops (5 gtts bid) over the *Gelfoam* and to wait 3 - 4 weeks before doing otoscopy to ensure healing has occurred
 - When performing canal wall down open cavity mastoidectomy, the 1st author places temporalis fascia over the reconstructed area, followed by *Gelfoam*. This is covered with a strip of surgical glove which serves as an inert barrier so that when the doctor subsequently removes the gauze from the mastoid cavity, the surgical reconstruction is not disrupted. Once the gauze and strip of glove are removed, ciprofloxacin eardrops (5 gtts bid) are placed over the *Gelfoam*. Otoscopy is performed 3-4 weeks later to ensure healing has taken place
6. It is imperative to continue to communicate with the doctor who is managing the patients postoperatively, also to advise how to manage delayed complications such as swelling, discharge, facial paralysis, vestibular dysfunction, or hearing loss. The 1st author does this through though internet based communication platforms

Recommended reading

- Local and regional anaesthesia techniques for otologic (ear) surgery <https://vula.uct.ac.za/access/content/group/ba5fb1bd-be95-48e5-81be-586fbaeba29d/Local%20and%20regional%20anaesthesia%20techniques%20for%20otologic%20ear%20surgery.pdf>
- Endoscopic cholesteatoma, tympanoplasty and middle ear surgery <https://vula.uct.ac.za/access/content/group/>

[ba5fb1bd-be95-48e5-81be-586fbaeba29d/Endoscopic%20cholesteatoma%20and%20middle%20ear%20surgery.pdf](https://vula.uct.ac.za/access/content/group/ba5fb1bd-be95-48e5-81be-586fbaeba29d/Endoscopic%20cholesteatoma%20and%20middle%20ear%20surgery.pdf)

- Hammer and gouge for cholesteatoma
<https://vula.uct.ac.za/access/content/group/ba5fb1bd-be95-48e5-81be-586fbaeba29d/Hammer%20%20Gouge%20Mastoidectomy%20for%20Cholesteatoma-1.pdf>
- Hammer and gouge for acute mastoiditis
<https://vula.uct.ac.za/access/content/group/ba5fb1bd-be95-48e5-81be-586fbaeba29d/Hammer%20%20Gouge%20Mastoidectomy%20for%20acute%20mastoiditis-1.pdf>
- Addressing ear and hearing care through task sharing: the Malawian experience
- ENT Outreach in Africa: Rules of Engagement
<http://journals.sagepub.com/doi/abs/10.1177/2473974X18777220>

How to cite this chapter

Wagner R, Torr G. (2015). Otology outreach surgery techniques under local and regional anaesthesia. In *The Open Access Atlas of Otolaryngology, Head & Neck Operative Surgery*. Retrieved from <https://vula.uct.ac.za/access/content/group/ba5fb1bd-be95-48e5-81be-586fbaeba29d/Otology%20outreach%20surgery%20techniques%20under%20local%20and%20regional%20anaesthesia.pdf%20>

Authors

Richard Wagner MD, FACS
Director, Global ENT Outreach
Coupeville, WA, 98239, USA
rwagner@geoutreach.org

Greg Torr MBChB, FCA (SA)
Anaesthetist
Cape Town, South Africa
gregtorr@mweb.co.za

Editor

Johan Fagan MBChB, FCS (ORL), MMed
Emeritus Professor and Past Chair
Division of Otolaryngology
University of Cape Town
Cape Town, South Africa
johannes.fagan@uct.ac.za

**THE OPEN ACCESS ATLAS OF
OTOLARYNGOLOGY, HEAD &
NECK OPERATIVE SURGERY**
www.entdev.uct.ac.za



The Open Access Atlas of Otolaryngology, Head & Neck Operative Surgery by [Johan Fagan \(Editor\) johannes.fagan@uct.ac.za](mailto:johannes.fagan@uct.ac.za) is licensed under a [Creative Commons Attribution - Non-Commercial 3.0 Unported License](https://creativecommons.org/licenses/by-nc/3.0/)

