

# OPEN ACCESS ATLAS OF OTOLARYNGOLOGY, HEAD & NECK OPERATIVE SURGERY



## DENTAL EXTRACTION TECHNIQUE FOR ENT AND HEAD & NECK SURGEONS Evan Rabie, Johan Fagan

While dental extraction should ideally be done by trained dental surgeons, head and neck surgeons often extract teeth in the operating room in patients when undergoing ablative cancer surgery. This is particularly true in resource constrained settings.

This chapter is a practical guide on how to perform dental extractions and to deal with common complications. As head and neck surgeons generally extract teeth in anaesthetised patients undergoing head and neck cancer surgery, local anaesthesia techniques are not discussed.

### Broad indications for dental extraction in oral cavity cancer

- Preventing osteoradionecrosis
- Achieving an adequate resection margin when tumour extends close to teeth
- Doing an osteotomy through a dental socket rather than between two teeth to avoid devitalising both teeth
- Creating a gap for the pedicle of a [buccinator myomucosal flap](#), [buccal fat pad flap](#) or [nasolabial flap](#)
- Extracting teeth with a marginal mandibulectomy

### Osteoradionecrosis (Figures 1, 2)

The incidence of osteoradionecrosis has reduced in recent decades with the advent of megavoltage intensity modulated radiotherapy (IMRT). Two theories have attempted to describe the pathophysiology of ORN. Marx (1983) described a hypocellular-hypovascular-hypoxic mechanism.<sup>1</sup> A hypoxic environment devoid of reparative cells was thought to predispose patients to chronic nonhealing wounds. This theory however does not explain the progressive nature of ORN. A 2<sup>nd</sup> theory described by

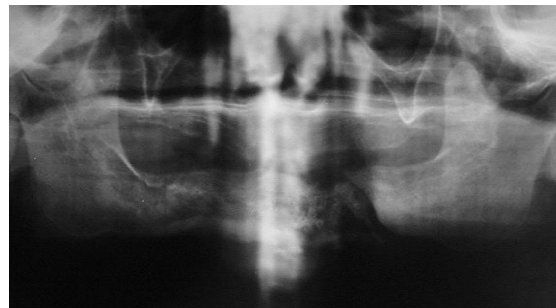

Figure 1: Osteoradionecrosis of mandible

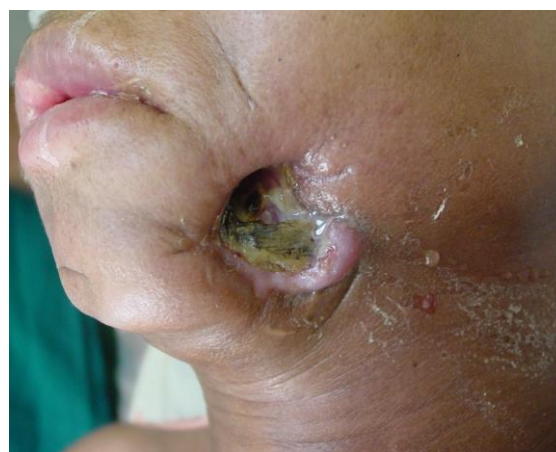

Figure 2: Osteoradionecrosis of mandible

Delanian (2004) postulated a radiation induced fibroatrophic mechanism (RIF).<sup>2</sup> An inflammatory cascade leading to dysregulated myofibroblast function is said to be responsible for the progressive fibrosis seen with ORN. These two theories have shaped our treatment philosophies. Marx's 3-H theory led to the widespread use of hyperbaric oxygen therapy whereas Delanian's fibroatrophic theory led to medical treatment using pentoxifylline, tocopherol and clodronate (Pentoclo).<sup>2,3</sup> Currently, there is insufficient evidence to support either of these management modalities to prevent or treat ORN.<sup>4-8</sup> In the absence of universally effective treatment, ORN is a potentially catastrophic complication of head and neck radiotherapy. The adage "prevention is the best form of cure" is especially true for ORN.

## **Strategies to reduce risk of ORN**

Strategies to prevent ORN can be thought of as pre- and postradiotherapy. Approximately one third of ORN is precipitated by dentoalveolar surgery. Reducing the likelihood of future dental complications that may require dental extractions reduces the risk of ORN.

**Pre-radiotherapy dental evaluation by a dentist is the cornerstone of a preventative strategy.** The decision whether to extract or not to extract is multifactorial. There are no universally accepted guidelines for clinicians. Factors that need to be considered in this multivariate equation include patients' dental IQ, dental history, existing dental pathology, access to frequent follow-up, preventative dental treatments and other risk factors for development of ORN.

Patients can be grouped as **high risk or low risk** based on the above factors. **High risk patients include the following:**

1. Low dental IQ
  - a. Poor oral hygiene
  - b. Cariogenic diet
  - c. Irregular dental visits
2. Dental history
  - a. Multiple missing teeth
  - b. Multiple restorations
  - c. History of periodontitis
3. Existing dental pathology
  - a. Gingivitis / periodontitis
  - b. Dental caries +/- pulpitis
  - c. Periapical lesions
  - d. Root rests
  - e. Odontogenic cysts or tumours
  - f. Unopposed / non-functional dentition or over-erupted teeth
4. Access to dental care: Patients not amenable to frequent dental follow-up and access to preventative treatments (not always available in resource constrained settings)
5. Other risk factors
  - a. Active smokers
  - b. Long-term steroid use

- c. High cumulative radiation dose
- d. Poor dexterity precluding selfcare e.g., severe arthritis, stroke, Parkinson's disease

Clinicians should adopt a **low threshold for dental extraction in patients categorised as high risk**. On the contrary, patients with a high dental IQ, healthy minimally restored dentition and readily amenable to follow-up and preventative treatment can safely maintain their dentition.

## **Pragmatic approach to prevent ORN**

### **Preoperative/pre-radiotherapy assessment**

- **Dental panoramic X-ray** (Panorex) to assess dental or osseous pathology
- **Clinical examination**
  - Periodontal assessment: Periodontal probing that causes bleeding on probing (BOP) or that identifies a gingival sulcus  $\geq 4\text{mm}$  signifies gum disease and requires treatment (*Figure 3*)
  - Dental assessment for dental caries, leaking/fractured restorations, severe attrition, erosion, abfraction and root rests
- **Educate patients** about importance of meticulous oral hygiene and fluoridation and lifelong regular dental check-ups

### **Definitive dental treatment prior to radiotherapy**

- Restore at-risk teeth
- Professional dental cleaning
- Professional fluoride application
- Treat periodontal disease or extract teeth with high dose radiation if
  - Gingival sulcus depth of  $\geq 5\text{mm}$  (normal  $\leq 3\text{mm}$ ) (*Figure 3*)
  - Refractory periodontitis
  - Evidence of root canal pathology: pain, swelling, apical radiolucency (*Figure 4*)

- Teeth that do not contact opposing teeth as these tend to over-erupt and cause injury to the opposing jaw's soft tissues over time

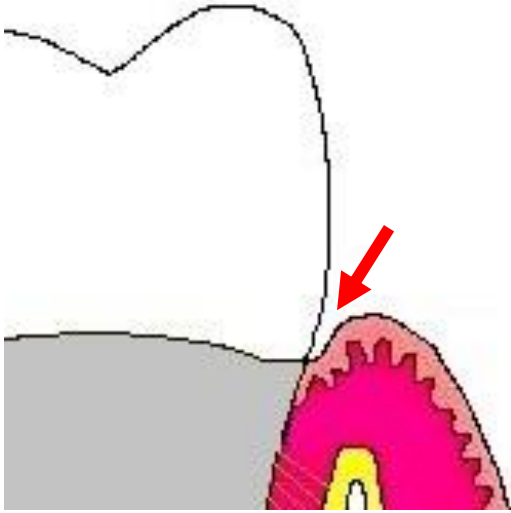


Figure 3: Gingival sulcus

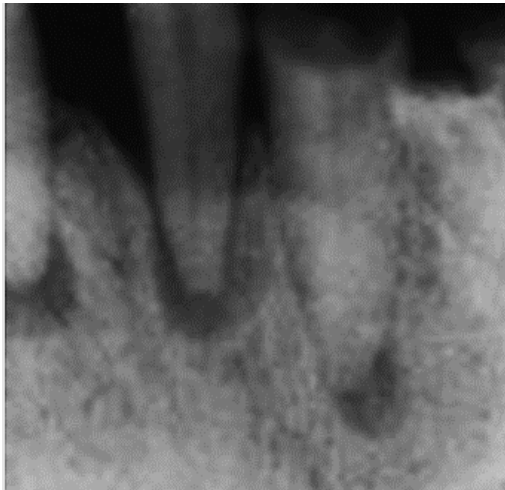


Figure 4: Apical radiolucencies

- Extractions are reserved for
  - “High risk” patients
  - Teeth deemed unsalvageable
  - Severely carious teeth
  - Mobile teeth
  - Teeth with large fillings, fractures, occlusal wear
  - Sensitivity to percussion
  - Retained dental roots
- Teeth should be *extracted at least 21 days prior to radiation therapy to allow soft tissue healing* (often done at time

of primary ablative surgery in oncology setting)

- *Use minimally traumatic dental extraction techniques*
- *Ensure that bone is covered by healthy mucosa prior to commencing radiotherapy*

#### *Dentoalveolar surgery after radiotherapy*

Dentoalveolar surgery after radiotherapy presents a clinical conundrum due to the increased risk of ORN following dental extraction in irradiated patients. Several “prophylactic” strategies have been proposed. These include perioperative hyperbaric oxygen therapy or perioperative pentoxifylline and tocopherol. Perioperative hyperbaric oxygen therapy using Marx’s 20/10 protocol was the standard of care in the USA for decades.<sup>1,9</sup> A subsequent randomised controlled trial (HOPON-study) failed to show benefit for hyperbaric oxygen over extraction only.<sup>10</sup> Hyperbaric oxygen chambers are also generally not available in developing countries. Similarly, perioperative use of pentoxifylline and tocopherol is not supported by data. In an era of evidence-based medicine, it is imperative that clinicians who use these modalities should be doing so in well-designed studies.

#### *A pragmatic approach to extractions in irradiated patients*

*Alternatives to extractions should be considered.* In some instances, teeth can be managed with conventional restorative techniques (fillings) or endodontics (root canal treatment). Because extracting teeth in an irradiated mouth is associated with increased risk of ORN, such patients should ideally be managed by *maxillofacial and oral surgeons who are trained at removing teeth with minimal trauma.*

*Guiding principles that can make extractions safe in an irradiated field when extractions are unavoidable, and a dental*

*specialist is not available are the following:*

- Consent patients about risk of ORN following extractions (Large systematic reviews estimate the risk to be 2-3% in the era of IMRT)<sup>11</sup>
- Administer preoperative systemic antibiotics (amoxicillin/clindamycin) at least 30min prior to extraction and continue for 5 days (anecdotal)
- Disinfect the mouth with 0.2% chlorhexidine mouth rinse prior to extraction
- Do the extraction in such a way so as ***not to disrupt the periosteum overlying the alveolar bone***. Much of the blood supply of the alveolar bone is derived from the periosteum. Hence, raising a mucoperiosteal flap for the purpose of primary closure is counterintuitive. Primary alveoplasty (removing sharp interdental septa or bony spicules) without disrupting the periosteum can be considered
- Extract the upper teeth before the lower teeth to limit the risk of debris from the upper extractions falling into exposed lower dental sockets (only relevant if extractions performed under local anaesthesia in a chair)
- Prescribe 0.2% chlorhexidine mouth rinse postoperatively (in addition to extended antibiotic prophylaxis) until soft tissue healing has occurred

Numerous intraoperative measures have been advocated with variable results e.g., noradrenaline, non-lignocaine local anaesthetic, extracting  $\leq 3$  teeth per session and various antibiotic and biological dressings. None are supported by robust data.<sup>11</sup> One modality deserves special mention: platelet rich fibrin (PRF) is widely used in oral surgical practice to facilitate healing of bone grafts but does not seem to benefit irradiated patients requiring extractions.<sup>12</sup>

## Dental anatomy relevant to extractions

### *Numbering conventions*

Only adult dentition is discussed as oral cancer is rare in children. Adults have 32 teeth. Three numbering conventions are commonly used (*Figure 5*). The *Universal Numbering System* is used in the USA; the *FDI two-digit system* is used throughout the rest of the world (including South Africa).<sup>13</sup> The *Palmer system* is largely of historical value. ***In this chapter the FDI two-digit system is described.***

### *FDI numbering system (Figures 5a,b)*

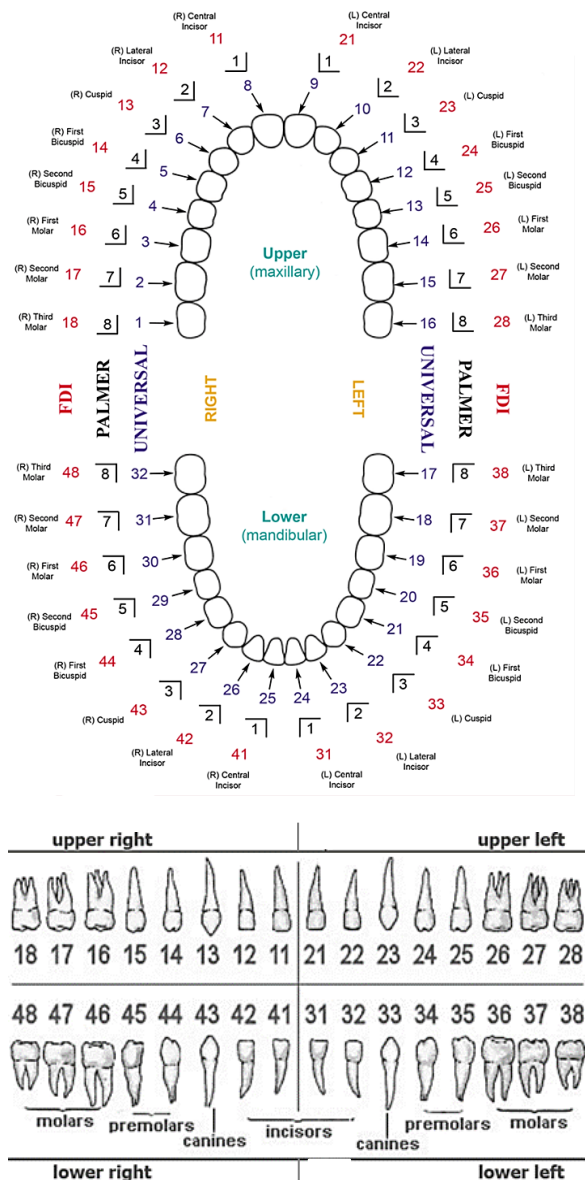
The mouth is divided into 4 quadrants. The 1<sup>st</sup> quadrant is located on the upper right of the mouth (from midline / upper central incisor to 3<sup>rd</sup> molar), the 2<sup>nd</sup> quadrant is located on upper left, the 3<sup>rd</sup> quadrant is located at lower left (from midline/ lower central incisor to 3<sup>rd</sup> molar) and the 4<sup>th</sup> quadrant is located at lower right. The first of the two digits indicates the quadrant the tooth is located in.

The 2<sup>nd</sup> digit is dictated by the type of tooth (*Table 1*). These teeth (when not transposed) are numerically in order from central incisor (1) to 3<sup>rd</sup> molar (8).

Hence “46” indicates a right lower (4) first molar (6). And “23” indicates a left upper (2) canine (3).

1	Central incisor
2	Lateral incisor
3	Canine (cuspid)
4	First premolar (bicuspid)
5	Second premolar (bicuspid)
6	First molar
7	Second molar
8	Third molar (wisdom tooth)

*Table 1: Numbering of individual teeth*



Figures 5a,b: FDI Dental Numbering Systems for permanent teeth<sup>13</sup>

Duplication (supernumerary) teeth are annotated using a lowercase letter a-b-c depending on the number of supernumerary teeth. “Extra” third molars are annotated by a second digit nine (9). Hence an additional lower right first premolar would be annotated as “44b”. An additional right upper wisdom tooth would be annotated “19”.

### Generic dental anatomy

A basic knowledge of the anatomy of the dental roots is essential as it varies depending on the type of tooth and has a bearing on the extraction technique. Figure 6 illustrates the basic anatomy of the tooth, the gingiva and dental socket.

strates the basic anatomy of the tooth, the gingiva and dental socket.

### Bony anatomy

The upper and lower jaws consist of dentoalveolar bone (housing the teeth) overlying the maxillary and mandibular basal bones. Although these bones are continuous, they are embryonically distinct.

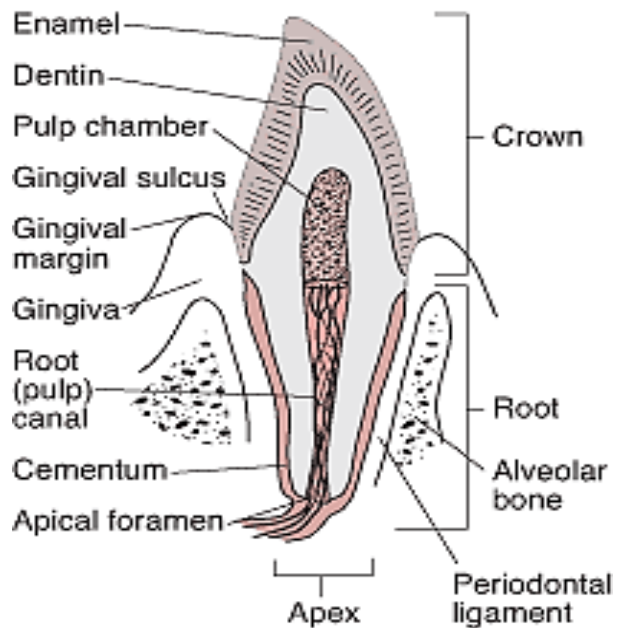


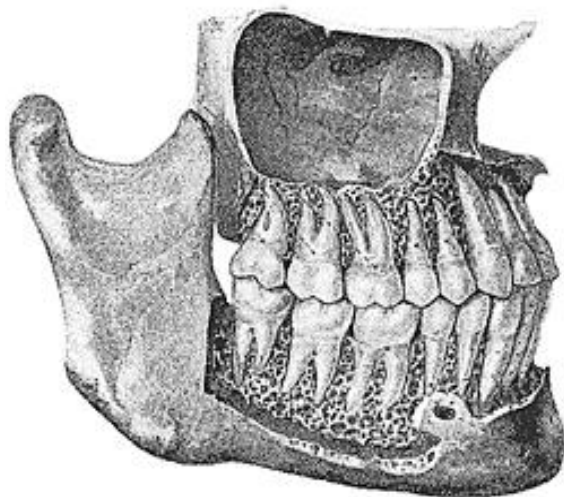
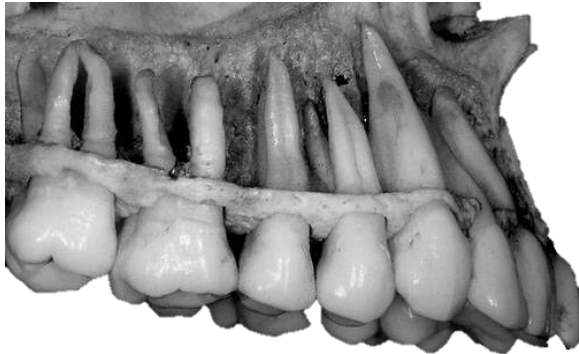Figure 6: Basic structure of tooth

Teeth are housed in *dental sockets* formed by *alveolar bone*. A thin layer of cortical bone (*lamina dura*) lines the dental sockets. This layer of bone serves as attachment for the periodontal ligaments (a complex network of collagen fibers that connect the tooth root to the surrounding bone). **During extraction, the bony socket is carefully “stretched”, and the periodontal ligaments are disrupted before the tooth is delivered into the mouth.** The roots of multirooted teeth are separated by interradicular bone which can be trimmed to prevent it protruding into the oral cavity.

### Anatomy of dental roots

Figures 7 and 8 show the complex and varied root configurations of teeth. Table 2 lists the most common root configuration

for each tooth. A knowledge of the roots is key to extraction technique and to avoid breaking off the roots; and should a root break off, how to go about extracting the root safely.



Figures 7a, b: Complex root configurations of upper teeth

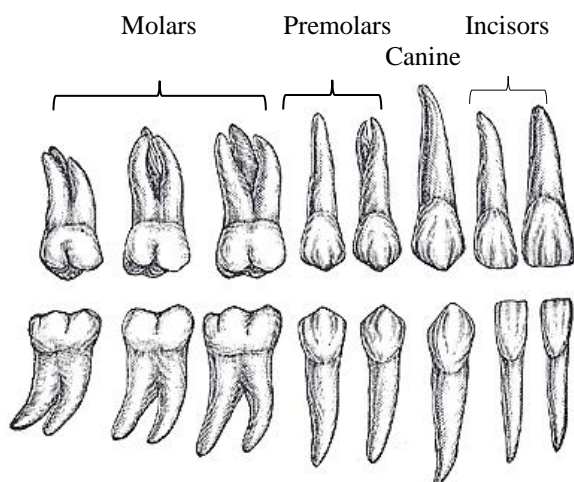


Figure 8: Root configurations

Maxillary dentition	
FDI	Configuration
1	Conical
2	Conical
3	Ovoid
4	2 rooted (1 buccal, 1 palatal)
5	Figure 8 / hourglass shaped
6	Trifurcated (3 roots: 2 buccally & 1 palatally)
7	
8	Mostly conical
Mandibular dentition	
1	Flat/ Ribbon-like
2	Flat/ Ribbon-like
3	Ovoid
4	Ovoid or figure 8/ hourglass shaped
5	
6	Bifurcated (2 roots: 1 anterior & 1 posteriorly)
7	
8	Highly variable. Mostly multirooted

Table 2: Common root configurations.

### Important anatomical relationships

The *inferior alveolar nerve* (IAN) courses along the *inferior alveolar canal*. It enters the mandible at the medial aspect of the mandibular ramus and exits at the mental foramen located inferior and lateral to the mandibular premolar tooth (Figure 9).

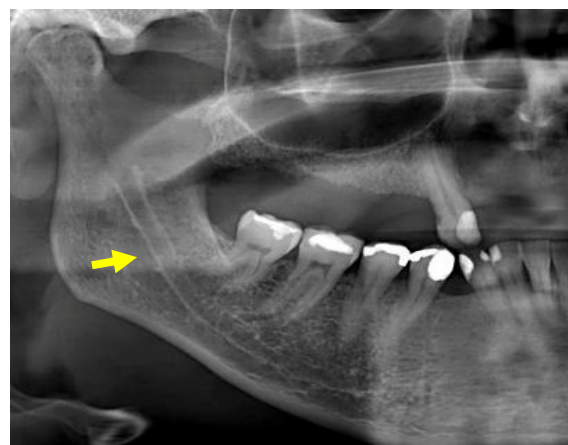


Figure 9: Note the inferior alveolar canal (arrow) and its proximity to the molar roots

The *IAN* is vulnerable to injury when drilling out a retained dental root, injury of which causes numbness of the ipsilateral teeth, gums and half of the lower lip. The

*lingual nerve* is found just deep to the lingual mucosa adjacent to the mandibular third molar. Incorrect application of dental forceps or incorrect use of a dental drill in this region places the lingual nerve at risk of injury resulting paraesthesia of the ipsilateral tongue. The roots of the **upper teeth may project into the maxillary sinus** (Figure 10). Extracting these teeth can cause an oroantral communication or dislodge teeth into the antrum.

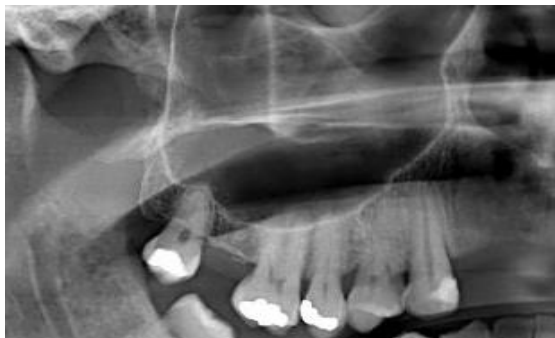

Figure 10: Note how roots of molar teeth protrude into floor of maxillary sinus

### Nerve supply to teeth and gums

When non-dentists (rarely) need to extract teeth under local anaesthesia, a basic knowledge of the nerve supply to the teeth and gums is important (Figure 11). Infiltration anaesthesia in the maxilla, or nerve blocks of the inferior alveolar nerves in patients undergoing dental extraction under general anaesthesia improves postoperative pain control and is a sound practice.

### Preoperative consent

**Frequently surgeons forget to consent head and neck cancer patients for intra-operative dental extraction.** Consent must include the following points:

1. Lower lip numbness
2. Tongue numbness
3. Jaw fracture
4. Oroantral communication
5. Osteoradionecrosis

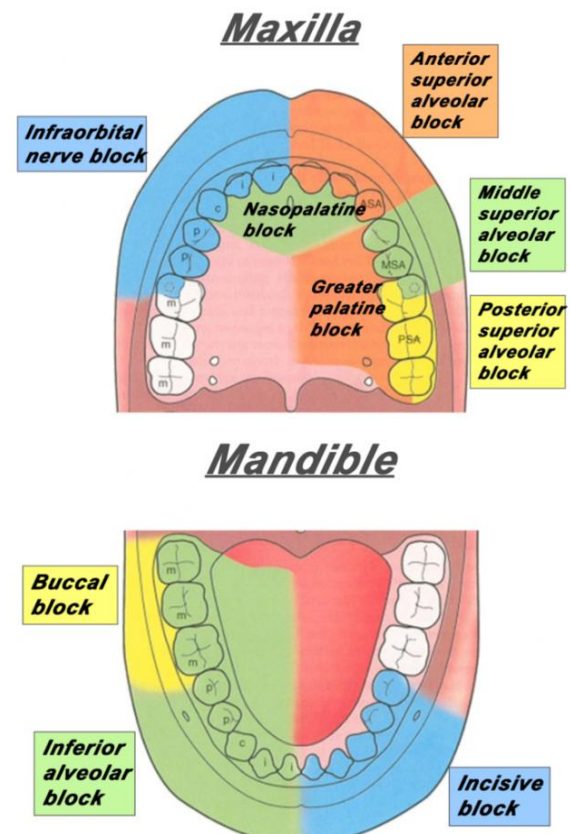


Figure 11: Nerve supply of teeth and gums

### Preoperative imaging

A Panorex is essential to direct the surgeon about what teeth to extract, to reveal retained dental roots, to delineate the inferior alveolar canal and the relations of the upper teeth to the maxillary antrum (Figures 9, 10) and to identify bony erosion by a malignancy.

### Perioperative antibiotics

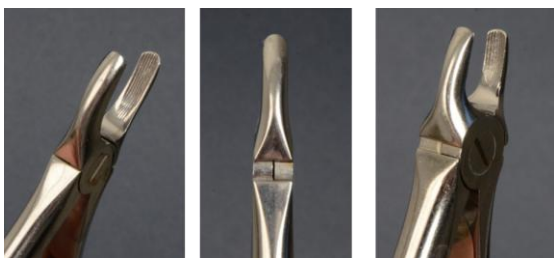
Resecting oral cancers constitutes clean-contaminated surgery. Therefore, patients should receive broad-spectrum antibiotics (Cefazolin/Clindamycin with Metronidazole) perioperative and for 24-hours postoperatively. There is **no need to extend postoperative antibiotic coverage beyond 24-hours when dental extractions are done prior to radiotherapy.**

## Instrumentation

A basic set of instruments to extract teeth under general anaesthesia includes the following:

### *Extraction forceps (Figures 12 -18)*

The blades vary in shape to accommodate the shapes of the roots. With upper forceps, the handles are in same axis as the blades. With lower forceps, the handles are at right angles to the blades.



*Figure 12: Straight forceps used for incisors and canines*



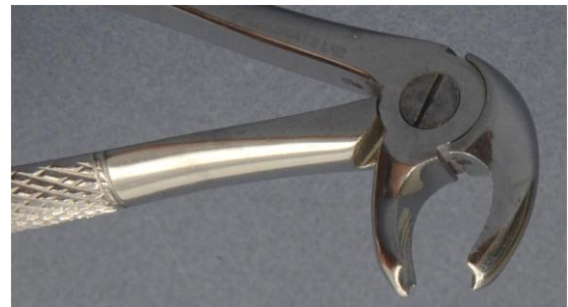*Figure 13: Upper premolar forceps have handles angled in mesial direction relative to the blades*



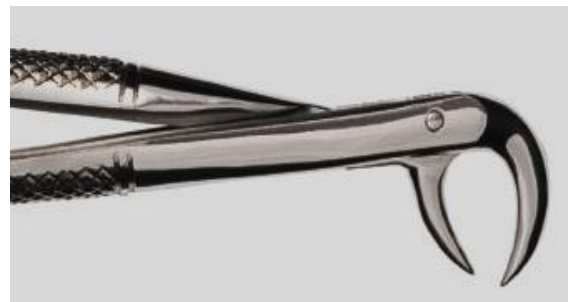*Figure 14: Upper molar forceps have a sharp beak on buccal side and rounded beak on palatal side to accommodate the 3 roots (2 buccal and 1 palatal). Because of the asymmetrical beaks, separate beaks are needed for the right and left sides*



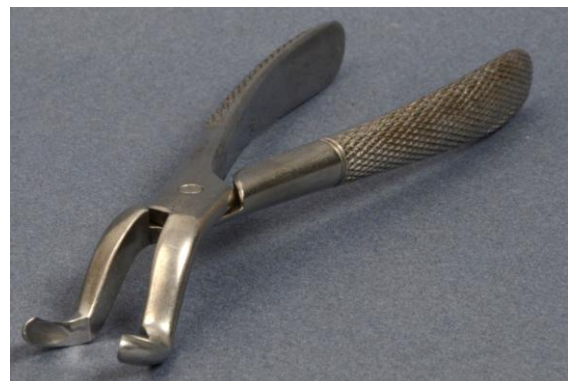*Figure 15: Lower mandibular incisor, canine and premolar forceps have two rounded blades*



*Figure 16: Lower molar forceps has a sharp beak on either side to accommodate the 2 fused mesial roots and the 1 distal root*



*Figure 17: Crown horn forceps are used to penetrate between the roots of lower molars especially if the roots are diverged*

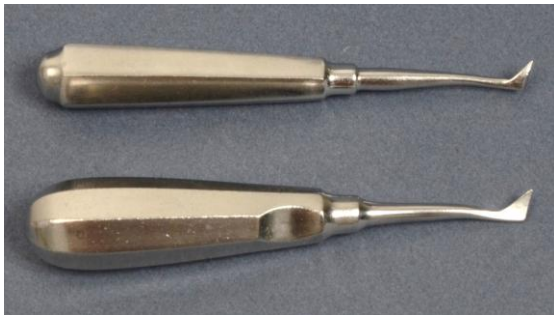

*Figure 18: Bayonet forceps provide added reach for the upper 3<sup>rd</sup> molars*

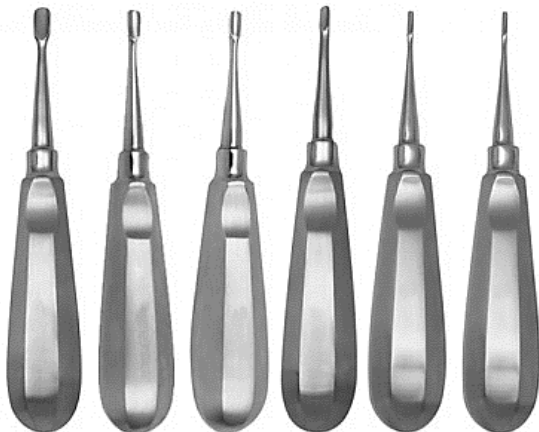


### ***Elevators (Figure 19 and 20)***

Dental elevators come in many shapes and sizes and are used in combination with forceps to apply force between the tooth and the alveolar bone. This aids extraction by disrupting the attachments of the tissues supporting the tooth, by expanding the dental socket, and by creating room for forceps to grip the tooth further down its root. It is also used to remove stumps of retained roots.



*Figure 19: Cryer elevators are used to remove fractured root fragments of mandibular molar teeth*



*Figure 20: Straight elevators include Coupland and Lindo-Levine elevators which are used to luxate teeth prior to extraction or to luxate fractured root fragments*

### ***Periosteal elevators (Figure 21)***


- Sharp-tipped end used to expand tooth socket
- Blunt end used to remove granulation tissues or raise a gum flap




*Figure 21: Example of periosteal elevator*

***Scalpel:*** No 15 blade to incise gums to raise a flap and gain access to a tooth

### ***Cheek retractors (Figure 22 and 23)***



*Figure 22: Example of cheek retractor*



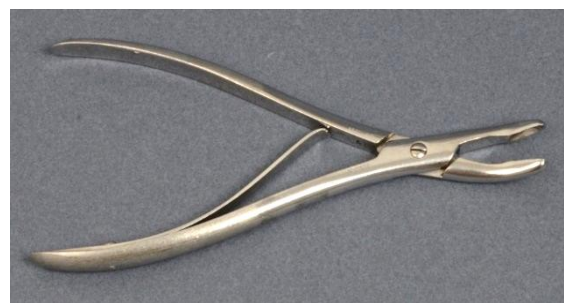*Figure 23: Austin retractor*

***Bone curettes:*** Mitchell's trimmer is used to remove granulation tissue from a socket



*Figure 24: Mitchell's trimmer*

***Bone rongeur and file:*** to smooth sharp bone edges following extraction



*Figure 25: Bone rongeur*



Figure 26: Bone file

**Surgical drill/bur:** To remove bone surrounding a tooth, to split a tooth and remove it in sections, or to drill out retained roots

**Chisels and mallet:** With the advent of rotary instruments, these have become obsolete, but may still be used to remove retained dental roots if powered instruments are not available

**Needle holder and sutures:** To approximate wound edges, control bleeding, limit wound size, and to prevent contamination of dental sockets with food debris. The authors use a 3/0 chromic suture on a reverse cutting 3/8 needle

### General principles

Dental extractions in head and neck cancer patients are performed in two settings: at the time of ablative surgery prior to radiotherapy; and when dental pathology develops after adjuvant radiotherapy requiring extraction of affected teeth. The latter are at risk of ORN after dental extractions.

The guiding principles are outlined on page 3 of this chapter: “*A pragmatic approach to dental extraction in irradiated patients*”.

### Summary of procedural steps

1. Consent
2. Perform extractions at least 21-days prior to starting radiotherapy
3. Disinfect the oral cavity before extractions with iodine or chlorhexidine mouth rinse
4. Administer perioperative antibiotics covering oral microbes as in clean-contaminated surgery. Only provide

*extended antibiotic “prophylaxis” in irradiated patients (anecdotal)*

5. Support the jaw between index finger and thumb when extracting a tooth
6. Use atraumatic surgical technique, ensuring minimal trauma with emphasis on not disrupting alveolar periosteum
7. Primary alveoplasty to remove sharp bony projections can be performed through the extraction socket without raising a mucoperiosteal flap
8. Meticulous post-extraction oral hygiene and antiseptic mouth rinse until soft tissues have healed
9. Data are insufficient to support use of hyperbaric oxygen therapy or the Pentoclo® regimen to prevent ORN after dental extractions

### Extraction Technique and Principles

Video on extraction technique

<https://www.youtube.com/watch?v=Usu5pTTz2SY>

1. Each type of tooth is extracted with a specific extraction forceps that is designed to accommodate the root morphology (*Table 3*)

Upper incisor	Straight rounded beak	Figure 12
Upper canine	Straight rounded beak	Figure 12
Upper premolars	Curved rounded beak	Figure 13
Upper molars	Curved rounded beak (palate) Sharp beak (buccally)	Figure 14
Upper 3 <sup>rd</sup> molars	Curved two rounded beaks	Figure 18
Lower incisors, canines, premolars	Right angle rounded beaks	Figure 15
Lower molars	Right angle two sharp beaks or “Cowhorn”	Figures 16, 17

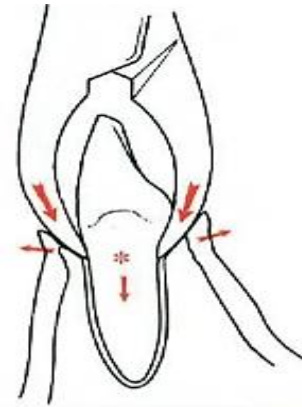
Table 3: Correct extraction forceps

- Apply forceps to the tooth **below the cemento-enamel junction** 2-3mm below the gingival margin (gum line) (*Figure 6*). This is the line where brittle enamel overlying the crown meets the more collagenous “flexible” cementum (bone like substance) overlying the roots of teeth.
- Extraction movements differ depending on the tooth to be extracted (*Table 4*)

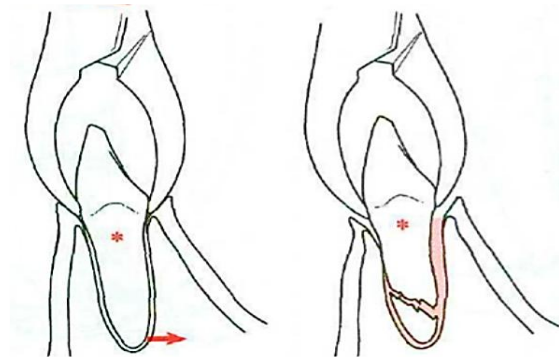
Upper incisor	Apical force Rotational movement
Upper canine	Apical pressure Buccolingual force followed by rotational movement
Upper premolars	Apical pressure Buccolingual force and deliver tooth buccally
Upper molars	Apical pressure Buccolingual force and deliver tooth buccally
Lower incisors, canines, premolars	Apical pressure Buccolingual force followed by rotational movement. Teeth delivered buccally
Lower molars	Apical pressure Figure of eight movement followed by buccally directed force and delivery of tooth buccally

*Table 4: Extraction movements*

- Expand the socket by inserting the beaks of the forceps into the periodontal ligament space and advancing it down the socket (*Figure 27*). This disrupts the periodontal ligament and permits the forceps to be placed further apically. Pressure should be gentle though forceful; avoid rapid, jerky movements
- Advance the beaks of the extraction forceps down the socket to shift the extraction fulcrum towards the apex and reduce chances of fracturing the root (*Figure 28*)

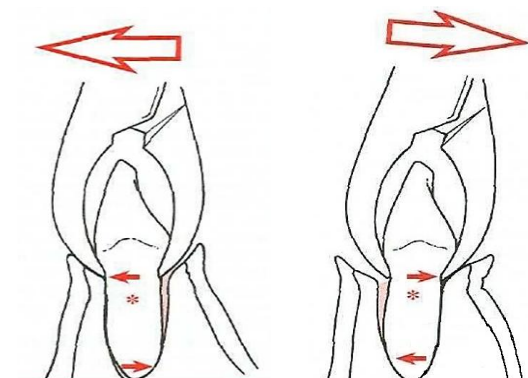


*Figure 27: Inserting beaks of extraction forceps into periodontal ligament space and advancing it down the socket*



*Figure 28: High fulcrum risks fracturing root; therefore, advance beak to move fulcrum towards the apex*

- Tilt the tooth in a buccal direction; this causes lateral displacement of the buccal plate of the crest of the alveolus (*Figure 29*)
- Apply pressure in a lingual direction to expand the lingual crestal bone (*Figure 29*)



*Figure 29: Pressure in buccal (left) and lingual (right) directions*

8. Rotate teeth with single roots *i.e.*, incisors, canines, and mandibular premolars to cause further expansion of the dental socket
9. Expand lower molar sockets by performing figure-of-eight movements
10. Once adequate expansion of the socket has been achieved, deliver the tooth by applying gentle traction to the tooth with buccally directed force

**“Tips” for extracting specific teeth**

The width of the beaks / blades of extraction forceps should fit snugly onto the root of the tooth. *If the ideal size is not available, then one should opt for smaller forceps.* Oversized forceps result in two-point contact when closed over a small root. Smaller forceps result in four-point contact when applied to the same root. This is true for the extraction of any tooth.

**Incisors (Figure 30)**

Extracting the anterior teeth is generally the least complex. Care should however be taken with extracting the lower incisors as they are prone to root tip fractures if poor technique is used.

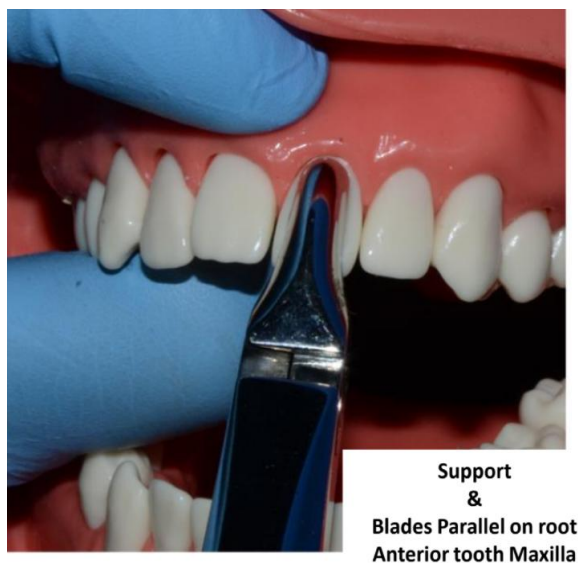


Figure 30: Extracting left maxillary central incisor

**Canines (Figure 31)**

Canine teeth can be very difficult to extract, even for experienced dental surgeons, because of the relatively long roots (Figure 8), the oval shape of the roots (precluding rotational movements) and the dense bone around the canine eminences of the maxilla and mandible. Resist the temptation to apply excessive force if at first the tooth does not “yield”. Be patient!

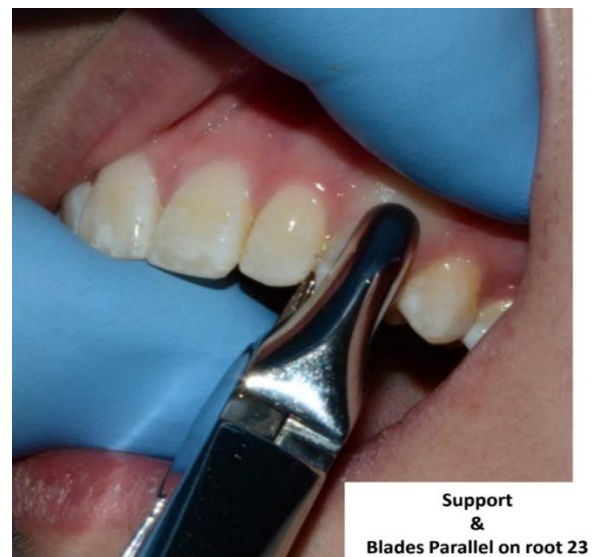

Figure 31: Extracting left maxillary canine

**Premolars (Figure 32)**

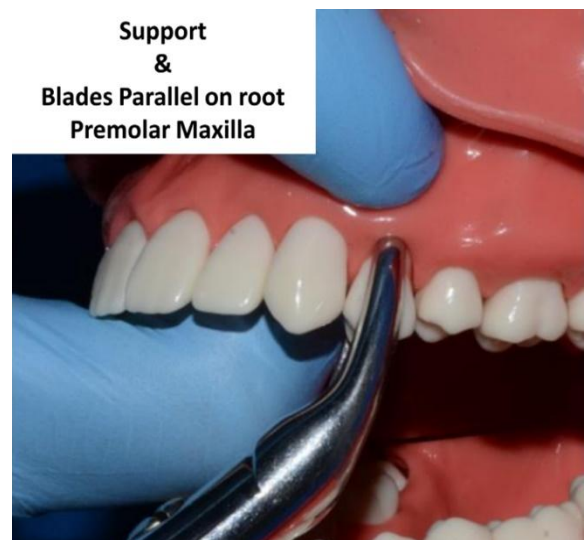


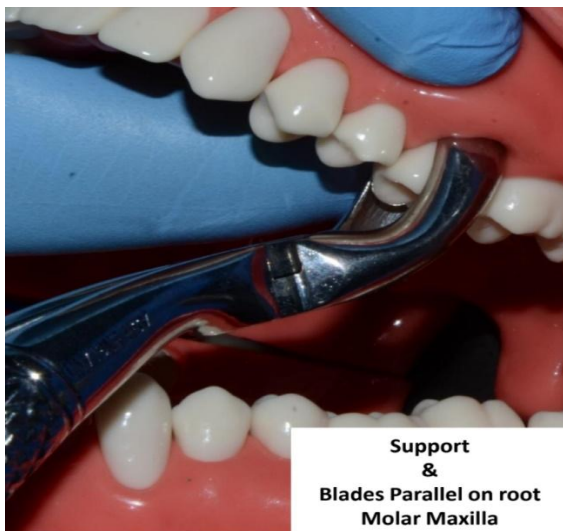
Figure 32: Extraction of left maxillary premolar tooth. Excessive buccal or palatal force can fracture one or both its thin roots

Both maxillary and mandibular premolars are considered “easy” to extract. The surgeon should however keep in mind that the *maxillary first premolars mostly have two roots* (buccal and palatal). Excessive force in either buccal or palatal directions often causes one or both roots to fracture.

### Upper Molars

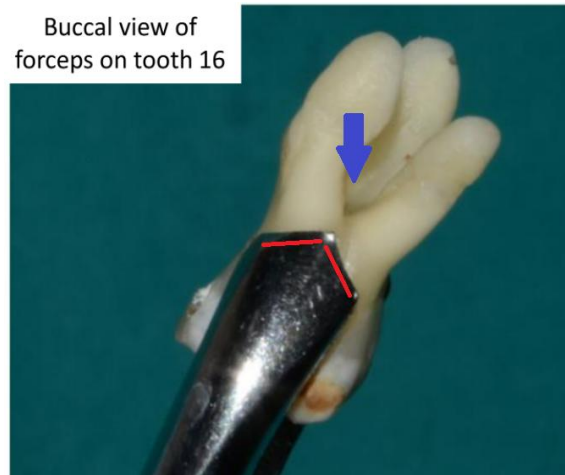
Pneumatisation of the maxillary antrum may extend to the bone between the roots of the maxillary molar teeth (*Figure 10*). Extracting these teeth can cause an oroantral communication that necessitates a buccal advancement flap (Rhemann-flap) to close the defect.

Correct placement of maxillary extraction forceps simplifies the extraction of these teeth (*Figure 33*).

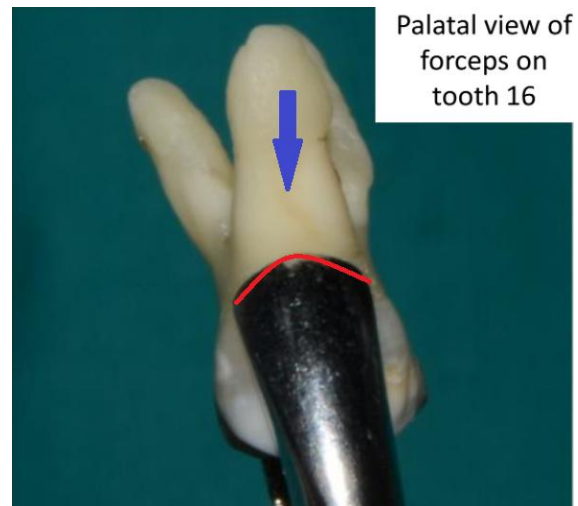


*Figure 33: Extracting maxillary molar*

The sharp beak should be positioned at the furcation (division) of the two buccal roots whereas the rounded beak should be securely positioned over the palatal root (*Figures 34 and 35*)



*Figure 34: Sharp beak (red) of left maxillary molar forceps is positioned at buccally positioned furcation (blue)*



*Figure 35: Rounded beak (red) of left maxillary molar forceps is positioned around palatal root of molar*

### Lower molars (*Figures 36, 37*)

Extracting mandibular molars can be complicated by dense alveolar bone. Application of force as low down on the root (fulcrum) as possible and taking time to “expand” the extraction socket will reduce fracturing the crown from the roots and necessitating a surgical extraction. Proper application of molar forceps further reduces the risk of fracturing the crown.

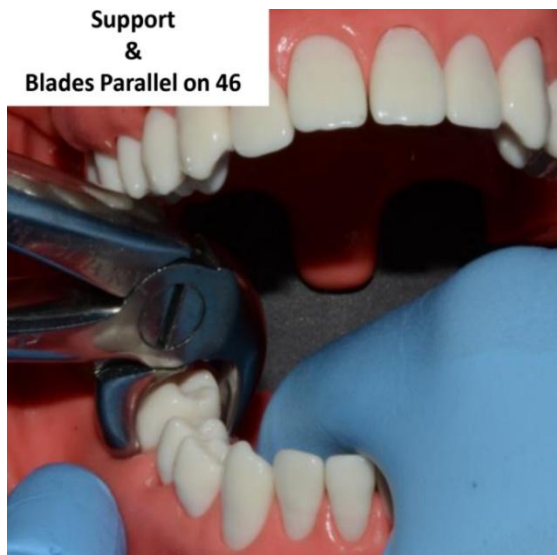


Figure 36: Extraction of right mandibular molar

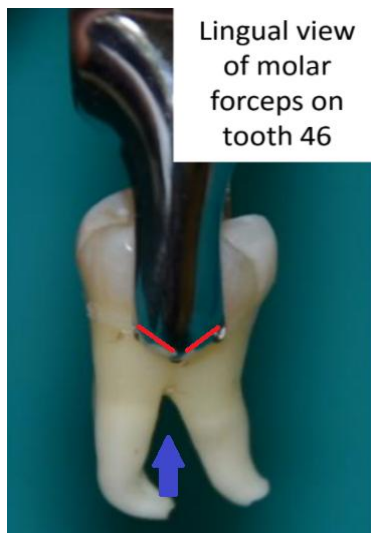

Figure 37: Mandibular molar forceps have two sharp / pointed beaks. The lingual beak is seen positioned at the lingual furcation of the mandibular molar tooth

### Difficult cases

The following are predictors of complex extractions:

1. Carious teeth
2. Large fillings / crowned teeth
3. Root canal treated teeth (brittle)
4. Absent dental superstructure
5. Curved or bulbous roots
6. Impacted or embedded teeth
7. Retained root(s)

### Surgical extraction of dental roots

Extractions are often complicated by fracturing of the crown from the root. It commonly happens when the surgeon applies force above the cemento-enamel junction *i.e.* to the crown and not the root surface. When this happens, the root(s) need to be retrieved using proper surgical technique.

#### Maxillary molars (Figure 38)

Maxillary molars mostly have three roots. A dental drill (703) is used to divide the buccal roots from the palatal and then the two buccal roots from one another. The roots can then be luxated and removed with narrow-bladed forceps.

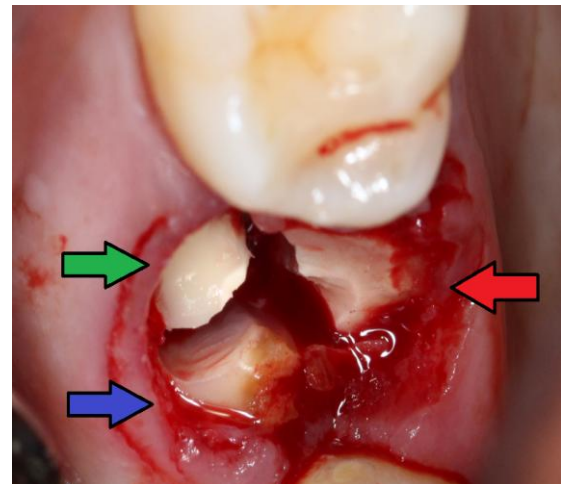


Figure 38: A dental drill (703) is used to divide the buccal roots (green and blue) from the palatal (red) and then the two buccal roots from one another

#### Mandibular molars: [Video Link](#)

Mandibular molars generally have two roots, one anteriorly and one posteriorly. A dental drill (703) is used to divide the anterior and posterior roots from one another (Figure 39). The roots can then be luxated and removed with either a curved elevator (e.g. Cryer) or a narrow-bladed forceps as two single rooted teeth

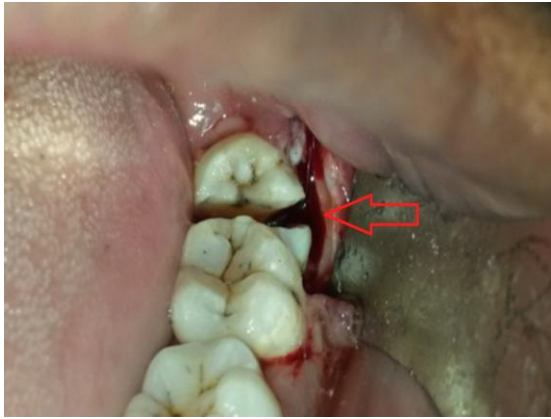

Figure 39: Mandibular molars generally have two roots, one anteriorly and another posteriorly. A dental drill (703) is used to divide the anterior and posterior roots from one another (arrow)

### Complications

Complications following dental extractions are rare, and include:

1. Bleeding
2. Infection
3. Alveolar osteitis (dry socket)
4. Inferior alveolar nerve injury
5. Lingual nerve injury
6. Oroantral fistula
7. Displacement into maxillary antrum
8. Displacement into infratemporal fossa
9. Mandibular fracture (Figure 40)
10. Fracture of the maxillary tuberosity
11. Temporomandibular joint dislocation

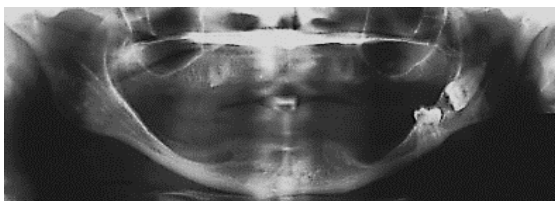


Figure 40: Severely resorbed mandible with impacted teeth is at high risk of fracture

### Dental extraction without dental forceps

In settings where a dental extraction set is not available, one may have to resort to unconventional techniques which may include using a dental elevator, a bone nibbler

(rongeur) or a Crile forceps. When using a bone nibbler, take great care to apply *extremely gentle pressure* to the tooth as it will otherwise fracture/cut through the tooth causing a retained root.

### Surgical extraction of dental roots without a dental drill

Once again, one may need to resort to unconventional techniques using either Cowhorn forceps or elevators or a hammer and osteotome/chisel to remove retained dental roots.

### Conclusions

Incorrect management of dentition in cancer patients requiring radiation, or who have already been radiated can have devastating long-term sequelae, especially in settings where resection of necrotic bone and reconstruction with a free fibula flap are not available. Early preoperative involvement of a dental surgeon to treat/extract poor dentition or to advise the surgeon doing the ablative surgery what teeth need to be extracted is a critical part of managing patients with cancers of the head and neck.

### References

1. Marx RE. A new concept in the treatment of osteoradionecrosis. *J Oral Maxillofac Surg* 1983; 41: 351-7
2. Delanian S and Lefaix J-L. The radiation-induced fibroatrophic process: therapeutic perspective via the antioxidant pathway. *Radiother Oncol.* 2004; 73: 119-31
3. Delanian S, Chatel C, Porcher R, *et al.* Complete restoration of refractory mandibular osteoradionecrosis by prolonged treatment with a pentoxifylline-tocopherol-clodronate combination (PENTOCLO): a phase II trial. *Int. J. Radiat. Oncol. Biol. Phys.* 2011; 80: 832-9
4. Chuang S-K. Limited evidence to demonstrate that the use of hyperbaric

- oxygen (HBO) therapy reduces the incidence of osteoradionecrosis in irradiated patients requiring tooth extraction. *J. Evid. Based Dent. Pract* 2012; 12: 248-50
5. Chouinard A-F, Giasson L and Fortin M. Hyperbaric oxygen therapy for head and neck irradiated patients with special attention to oral and maxillofacial treatments. *J Can Dent Assoc* 2016; 82: 1488-2159
  6. Patel V, Gadiwalla Y, Sassoon I, et al. Prophylactic use of pentoxifylline and tocopherol in patients who require dental extractions after radiotherapy for cancer of the head and neck. *Br J Oral Maxillofac Surg* 2016; 54: 547-50
  7. Rivero JA, Shamji O and Kolokythas A. Osteoradionecrosis: a review of pathophysiology, prevention and pharmacologic management using pentoxifylline,  $\alpha$ -tocopherol, and clodronate. *Oral Surg. Oral Med. Oral Pathol. Oral Radiol.* 2017; 124: 464-71
  8. Annane D, Depondt J, Aubert P, et al. Hyperbaric oxygen therapy for radionecrosis of the jaw: a randomized, placebo-controlled, double-blind trial from the ORN 96 study group. *J Clin Oncol* 2004; 22: 4893-900
  9. Cronje F. A review of the Marx protocols: prevention and management of osteoradionecrosis by combining surgery and hyperbaric oxygen therapy. *SADJ.* 1998; 53: 469-71
  10. Shaw RJ, Butterworth CJ, Silcocks P, et al. HOPON (Hyperbaric Oxygen for the Prevention of Osteoradionecrosis): a randomized controlled trial of hyperbaric oxygen to prevent osteoradionecrosis of the irradiated mandible after dentoalveolar surgery. *Int. J. Radiat. Oncol. Biol. Phys.* 2019; 104: 530-9
  11. Nabil S and Samman N. Incidence and prevention of osteoradionecrosis after dental extraction in irradiated patients: a systematic review. *Int J Oral Maxillofac Surg* 2011; 40: 229-43
  12. Palma LF, Marcucci M, Remondes CM, et al. Leukocyte-and platelet-rich fibrin

does not provide any additional benefit for tooth extraction in head and neck cancer patients post-radiotherapy: a randomized clinical trial. *Med Oral Patol Oral Cir Bucal* 2020; 25: e799

13. Harris EF. Tooth-coding systems in the clinical dental setting. *Dent Anthropol* 2005; 18: 43-9

### How to cite this chapter

Rabie E, Fagan JJ. (2021). Dental extraction technique for ENT and head and neck surgeons. In *The Open Access Atlas of Otolaryngology, Head & Neck Operative Surgery*. Retrieved from <https://vula.uct.ac.za/access/content/group/ba5fb1bd-be95-48e5-81be-586fbaeba29d/Dental%20extraction%20technique%20for%20ENT%20and%20head%20and%20neck%20surgeons.pdf>

### Author

Evan Rabie BChD, MBChB, MChD, FCMFOS (SA)  
Maxillofacial surgeon  
Department of Maxillofacial and Oral Surgery  
University of Pretoria  
Pretoria, South Africa  
[evan.rabie@gmail.com](mailto:evan.rabie@gmail.com)

### Co-author and Editor

Johan Fagan MBChB, FCS (ORL), MMed  
Emeritus Professor and Past Chair  
Division of Otolaryngology  
University of Cape Town  
Cape Town, South Africa  
[johannes.fagan@uct.ac.za](mailto:johannes.fagan@uct.ac.za)

**THE OPEN ACCESS ATLAS OF  
OTOLARYNGOLOGY, HEAD &  
NECK OPERATIVE SURGERY**  
[www.entdev.uct.ac.za](http://www.entdev.uct.ac.za)



The Open Access Atlas of Otolaryngology, Head &



Neck Operative Surgery by [Johan Fagan \(Editor\)](#)  
[johannes.fagan@uct.ac.za](mailto:johannes.fagan@uct.ac.za) is licensed under a  
[Creative Commons Attribution - Non-Commercial  
3.0 Unported License](#)

