

OPEN ACCESS GUIDE TO AUDIOLOGY AND HEARING AIDS FOR OTOLARYNGOLOGISTS



DIAGNOSTIC EVALUATION OF TYMPANIC MEMBRANES

Thorbjörn Lundberg, Claude Laurent, Robert Eikelboom

The most common middle ear diseases are otitis media with effusion (OME), acute otitis media (AOM) and chronic suppurative otitis media (CSOM). Diagnosing middle ear disease is based mainly on inspection of the tympanic membrane (TM) and indirect measurements of the status of

the middle ear. (Tables 1, 2; Figure 1) To improve diagnostic accuracy in general practice the important factors are assessment of the position and transparency of the TM, and use of pneumatic otoscopy and/or tympanometry ¹.

Diagnosis	Pneumatic otoscopy	Tympanogram	OM grade*	Description
Normal	Normal	Type A	Grade 0-1R	A transparent TM in a fairly normal position without signs of middle ear fluid together with a type A tympanogram or normal pneumatic otoscopy
OME	Impaired mobility	Type B or C	Grade 1F-3	A transparent TM with visible middle ear fluid or an opaque TM in a fairly normal position with a type B or C tympanogram
AOM**	Impaired mobility	Type B	Grade 3-5C	An opaque and bulging TM together with a type B tympanogram
CSOM	Impaired or no mobility	Type C (retraction) or B (perforation)	6	TM with chronic perforation and recurrent secretion/pus

* OM grade – image based grading scale for otitis media diagnosis (see Table 2 and Figure 3)

** Diagnosis of AOM is based on a combination of symptoms and signs. In some cases with OM grade scale-step 3 and tympanogram B an AOM diagnosis can be made in combination with symptoms e.g. otalgia and fever

Table 1: Diagnosis of otitis media

<p>Step 1: Tympanic membrane</p> <ol style="list-style-type: none"> 1) Transparency 2) Position 3) Mobility 4) Colour 5) Reflex 6) Surface structure 7) Patency <p>Step 2: Middle ear</p> <ol style="list-style-type: none"> 1) Fluid levels 2) Mobility 3) Pneumatic otoscopy 4) Tympanometry

Table 2: Evaluation of middle ear

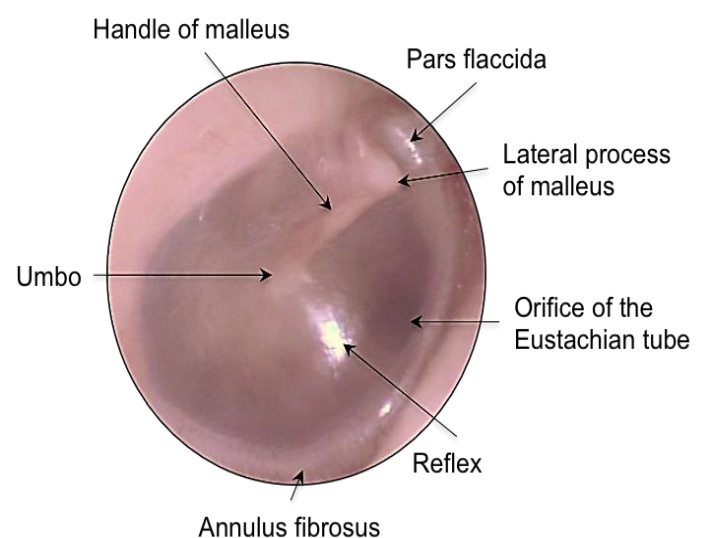


Figure 1: Surface anatomy of the normal tympanic membrane

Evaluation of tympanic membrane

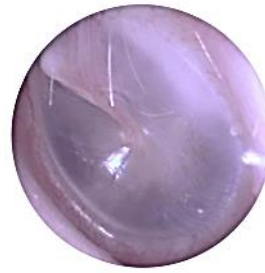Step 1

The 1st step to diagnose otitis media is to **recognise a number of different characteristics in the appearance of the TM** e.g. transparency, position, mobility, colour, reflex characteristics, surface structure and patency (Figure 2). A cloudy and bulging TM are strong indications of AOM. A chronic perforation may also be seen with secretions or severe retraction of the TM (CSOM). The most common characteristic of AOM is an opaque TM (100% of ears) and almost as common is a bulging TM (93% of ears) ². The 3rd most common characteristic of the TM in AOM is a white or yellow colour (64% of ears) with redness coming only 4th (58% of AOM) ².

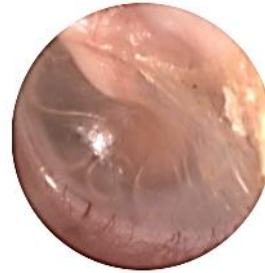However, clinicians often use redness as one of the most important diagnostic features to diagnose AOM; this has been found to lead to overdiagnosis of AOM ¹. The surface structure may also add information about inflammatory processes in the TM. The light reflex is normally of a triangular shape but may appear as a dot on a bulging or retracted TM or shattered in swollen TMs.

Step 2

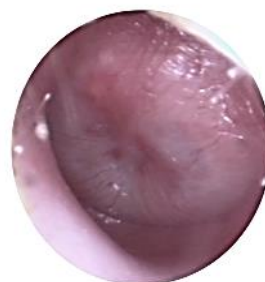
The second step in assessing otitis media is to **determine if there is a middle ear effusion, or a TM perforation** (high volume on tympanometry, >3cm³). An effusion can be seen through a transparent TM as fluid levels and/or air bubbles, whereas a bulging TM can be attributed to pronounced middle ear purulent secretion. However, a TM in a normal position may be opaque and then it can be difficult to see the secretion. Here both pneumatic otoscopy and tympanometry can be of help (Table 1). One requires an otoscope, plus a selection of ear specula that provide a tight seal with the ear canal, and an insufflator bulb (see



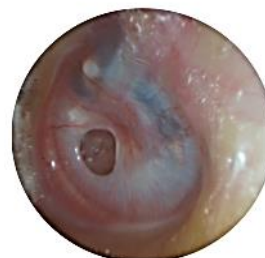Normal: Transparent TM in a normal position with no visible fluid levels. The reflex has a triangular shape and surface structure appears smooth



Otitis media with effusion: Transparent TM in normal position or slightly retracted with fluid levels visible. The reflex is dot-shaped, surface structure appears smooth



Acute otitis media: Opaque, bulging TM. The reflex is shattered, surface structure appears irregular. The normal anatomy cannot be assessed and the malleus handle is hidden by the bulging TM



Chronic suppurative otitis media: Perforated TM with or without secretion. Severe retraction of the TM and cholesteatoma may occur

Figure 2: Tympanic membrane appearances

chapter: [Pneumatic otoscopy and otoscopy](#)). With this equipment the air pressure in the external ear canal can be increased repeatedly to assess the mobility of the TM. An indirect sign of fluid behind the TM is a restriction of its mobility.

In a review of the literature sensitivity and specificity were found to be 94% and 80% respectively for pneumatic otoscopy to detect middle ear effusion ³. Similarly, in another study pneumatic otoscopy was

shown to improve sensitivity and specificity by 24% and 42%, respectively compared to otoscopy⁴.

A tympanometer can also be used to provide information on the mobility of the TM (*Table 1*; and chapter [Tympanometry](#)). An evaluation of middle ear fluid using tympanometry or pneumatic otoscopy has been found to be most important in improving diagnostic accuracy for otitis media in general practice^{1, 3, 4}

Grading OM observations

Visual assessment of the TM has its obstacles ranging from obscuring wax to an uncooperative child and faulty equipment. This is apart from the difficulty to interpret the findings once the TM is visualised. In order to guide the clinician a scoring system has been developed together with one image-based grading scale. This new image-based grading scale, the *OM grade scale* (*Table 3, Figure 3*), has been developed, validated and tested as a diagnostic guide for otitis media. The scale is based on the transparency and the position of the TM^{5, 6}.

Diagnosis of OM

A differential diagnosis of OM may be made when combining otoscopic observations, with the results from pneumatic otoscopy and/or tympanometry (*Table 1*).

Otitis media with effusion

Diagnostic criteria: Requires visible fluid levels or, in a case of an opaque TM, evaluation with pneumatic otoscopy or tympanometry (impaired mobility or type C or B tympanograms) (*Table 1*). There may be a temporary slight hearing impairment. OME is a dynamic process and may be preceding AOM or follow AOM. Therefore a distinct separation between OME

and AOM is in some cases difficult to make.

Grade	Subgrade	Description
0	0	Transparent TM in normal position
1	1	Transparent TM in normal position or slightly retracted with fluid level or fluid filled ME
2	2	Transparent TM in normal position or slightly retracted with turbid/opaque fluid level
3	3	Opaque appearance of TM in fairly normal position
4	4	Opaque appearance of TM and bulging
	5B	Opaque appearance of TM with bulla formations
5	5C	Contourless TM with wet appearance and swollen keratin patches, +/- pulsating pus from small perforation
	6	TM perforation, retraction pocket or cholesteatoma +/- purulent discharge

Table 3: Grading according to a modified OM grade scale including CSOM

Acute otitis media

Diagnostic criteria: A combination of acute onset of symptoms and characteristic TM changes. Symptoms include otalgia, fever, and symptoms attributable to an upper respiratory tract infection (URI). Signs required for the diagnosis are an opaque and bulging TM, often together with discoloration and sometimes increased vascularisation. A bulging TM has high diagnostic value. The *American Academy of Paediatrics (AAP)* states that the diagnosis of AOM can be made in the presence of a bulging TM or with acute onset of otorrhoea⁷. The diagnosis may also be established if there is a mild bulging of the TM together with recent onset of ear

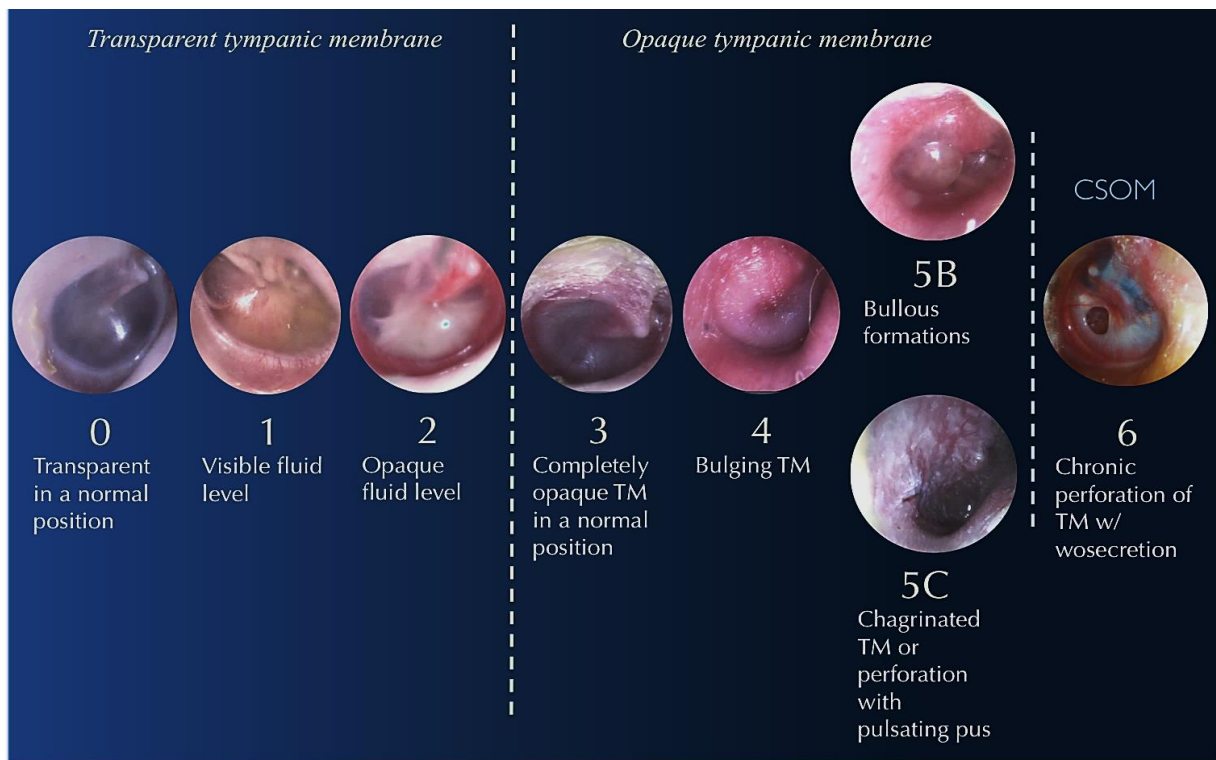


Figure 3: The modified OM grade scale including CSOM

pain. The appearance of the TM is usually described as thickened and opaque with an irregular surface structure and with a varying discoloration.

The TM can perforate and pus may pulsate out through the perforation; this is known as a perforated AOM. Furthermore, bullous formations can be found on the TM (bullous myringitis). This is mainly associated with AOM and rarely occurs without purulent middle ear fluid. If it does it is as a local inflammatory process in the TM.

In one study 76 - 89% of spontaneously draining ears were reported to have swollen keratin patches on the TM, sometimes called chagrinated⁸. The TM in those cases is reddish with white and elevated keratin patches together with a wet appearance. Common symptoms associated with AOM are otalgia, ear tugging, irritability, decreased play activity, decreased appetite, disturbed sleep and fever⁹.

Chronic suppurative otitis media

CSOM is defined as a chronic inflammatory process in the middle ear and mastoid cavity with current secretion through a perforation of the TM (open for >3 months)¹⁰. In CSOM one may also observe severe retractions of the TM as well as cholesteatoma formations (Figure 4) originating from a TM retraction or perforation of a retraction pocket¹¹.

Conclusions

Otitis media is common. Primary care providers can play an important role in diagnosing and managing the disease. Using otoscopy and this guide, the practitioner can recognise classic signs to determine the type and grade of otitis media by observing the tympanic membrane.

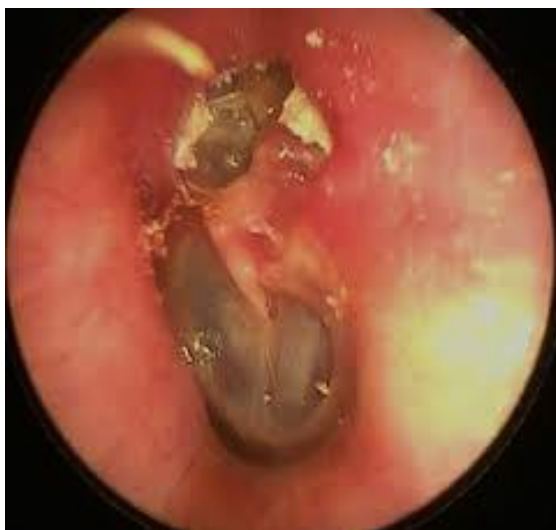

Figure 4. Left tympanic membrane (CSOM) with deep attic retraction and cholesteatoma (white keratin).

References

1. Blomgren K, Pohjavuori S, Poussa T, Hatakka K., Korpela R., Pitkäranta A. Effect of accurate diagnostic criteria on incidence of acute otitis media in otitis-prone children. 2004. *Scand J Infect Dis* 2004; 36: 6-9
2. Shaikh N., Hoberman A., Kaleida P. H., Rockette H. E., Kurs-Lasky M., Hoover H., et al. Otosopic signs of otitis media. 2011. *Ped Infect Dis J* 2011; 30: 822-6
3. [3] Takata GS, Chan LS, Morphey T, Mangione-Smith R, Morton SC, Shekelle P. Evidence assessment of the accuracy of methods of diagnosing middle ear effusion in children with otitis media with effusion. 2003. *Pediatrics* 2003; 112: 1379-87
4. Jones WS, Kaleida PH. How helpful is pneumatic otoscopy in improving diagnostic accuracy? 2003. *Pediatrics* 2003; 112: 510-3
5. Lundberg T, Biagio L, Laurent C, Sandström H, Swanepoel DW. Remote evaluation of video-otoscopy recordings in an unselected pediatric population with an otitis media scale. 2014. *Int J Ped Otorhinolaryngol* 2014; 78: 1489-95
6. Lundberg T, Hellström S, Sandström H. Development and validation of a new grading scale for otitis media. 2013. *Ped Infect Dis J* 2013; 32: 341-5
7. Lieberthal AS, Carroll AE, Chonmaitree T, Ganiats TG, Hoberman A, Jackson MA, et al. The diagnosis and management of acute otitis media. 2013. *Pediatrics* 2013; 131: e964-99
8. Neumark T, Ekblom M, Brudin L, Groth A, Eliasson I, Molstad S, et al. Spontaneously draining acute otitis media in children: an observational study of clinical findings, microbiology and clinical course. 2011. *Scand J Infect Dis* 2011; 43: 891-8
9. Shaikh N, Hoberman A, Paradise J L, Wald ER, Switze GE, Kurs-Lasky M, et al. Development and preliminary evaluation of a parent-reported outcome instrument for clinical trials in acute otitis media. 2009. *Ped Infect Dis J* 2009; 28: 5-8
10. WHO. Chronic suppurative otitis media. Burden of Illness and Management Options. 2004. 2004: 83
11. Acuin J. Chronic suppurative otitis media. 2007. *Clinical Evidence* 2007; 2007: 1-20

Authors

Thorbjörn Lundberg MD, PhD
 Family Medicine
 Department of Public Health & Clinical Medicine
 University of Umeå
 Umeå, Sweden
thorbjorn.lundberg@umu.se

Claude Laurent MD, PhD
 Professor in ENT/Audiology
 ENT Unit
 Department of Clinical Science
 University of Umeå

Umeå, Sweden
claude.laurent@umu.se

Robert H Eikelboom B.Eng, M.Appl Sc,
PhD
Ear Science Institute Australia
The University of Western Australia
Perth, Australia
rob.eikelboom@uwa.edu.au

Editors

De Wet Swanepoel PhD
Associate Professor
Department of Communication Pathology
University of Pretoria
Pretoria, South Africa
dewet.swanepoel@up.ac.za

Johan Fagan MBChB, FCS(ORL), MMed
Professor and Chairman
Division of Otolaryngology
University of Cape Town
Cape Town
South Africa
johannes.fagan@uct.ac.za

**OPEN ACCESS GUIDE TO
AUDIOLOGY & HEARING AIDS
FOR OTOLARYNGOLOGISTS**
<http://www.entdev.uct.ac.za>



The Open Access Atlas of Otolaryngology, Head & Neck Operative Surgery by [Johan Fagan \(Editor\)](mailto:johannes.fagan@uct.ac.za) johannes.fagan@uct.ac.za is licensed under a [Creative Commons Attribution - Non-Commercial 3.0 Unported License](https://creativecommons.org/licenses/by-nc/3.0/)