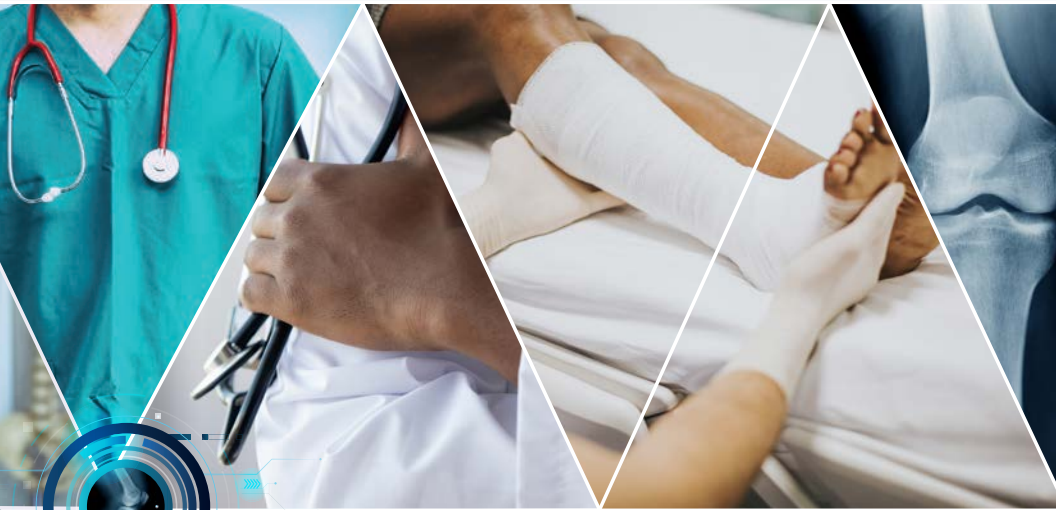

ORTHOPAEDICS



FOR PRIMARY
HEALTH CARE



LION

LEARNING INNOVATION VIA
ORTHOPAEDIC NETWORKS

EDITOR: **MICHAEL HELD**

UNIVERSITY OF CAPE TOWN'S **ORTHOPAEDIC DEPARTMENT**

Orthopaedic emergencies

by Stephanie Roche, Kim Laubscher, Nicholas Kruger, Stefan van der Walt & Stephen Roche

Learning objectives

- 1. Red flags in the outpatient setting: infection, malignancy and spinal disorders.
- 2. Red flags in the Orthopaedics ward: fat embolism, compartment syndrome, Paediatrics: non-accidental injury.

Orthopaedic red flags

Many orthopaedic problems can be managed in the primary care setting. To practice safely at this level of care, medical officers need to know which patients to investigate and follow-up and when to refer patients for urgent or emergency management.

Initial assessment includes a thorough history of the presenting complaint and medical history (particularly concerning trauma, cancer, immunosuppressive conditions or medications), and a musculoskeletal and neurological examination. The crucial warning signs on history and examination that suggest serious pathology and which might warrant referral or specialist advice, are listed in the table.

Clinical red flags	
History:	
Local	Rapidly progressive symptoms Red, hot swollen joint Pain interrupting sleep
Systemic	Loss of appetite Loss of weight Fever Change in bowel or bladder function Weakness or change in sensation History of cancer History of intravenous drug use Immunosuppression
Examination	Fever >38°C Inability to bear weight on joint Red/hot /swollen joint Saddle anaesthesia Lower motor neuron signs Reduced anal tone Bilateral upper motor neuron signs

Malignancy

Malignant tumours of soft tissue and bone should be excluded in all patients with a mass or lesion with any of the characteristics listed in the table. Imaging (ultrasound for soft tissue masses, radiograph for bony masses) and referral to a specialist should be the next step. See the specific chapter for more information.

Red flags for masses
Rapid growth
Pain
>5cm diameter
deep to fascia

Infection

Primary septic arthritis and osteomyelitis are important differentials in patients presenting with musculoskeletal pain or swelling. Delay in diagnosis (even by hours) can result in progressive joint destruction. Importantly, obvious signs of inflammation may be absent in immunosuppressed patients, and investigations may be warranted in the absence of systemic signs. In immunocompetent patients, one or more of the following features listed in the table alongside are present.

Differential diagnosis:

- **Blood results** as above (WCC, ESR or CRP, blood culture).
- **Uric acid and inflammatory arthritis markers.** Gout and inflammatory arthritis will be on the list of differentials and may need to be excluded.

- **Synovial fluid aspiration** (assess the appearance of fluid, cells and differential count, crystals, Gram stain and culture) -
- **X-rays**

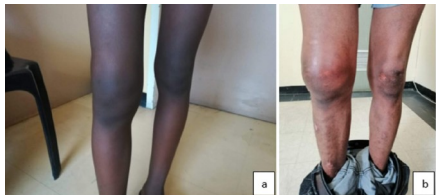
Differential diagnosis:

- Inflammatory arthritis, for example, rheumatoid arthritis, psoriatic arthritis (although more likely oligo- or polyarthritis, as opposed to monoarthritis)
- Osteoarthritis
- Gout, pseudogout
- Trauma (for example, haemarthrosis)

For treatment, please refer to the respective chapter on infections.

Red flags for infections		
Systemic	Temperature	>38°C
	Leukocytes	>12 000 x 10 ⁹ /L
	Respiratory rate	elevated
	Heart rate	elevated
Orthopaedic	Inability to weight bear	
Blood results	ESR	>40mm/hr
	CRP	elevated

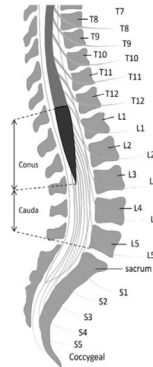
Red flags which should raise suspicion of infections.



Clinical pictures of swollen, warm, red, painful joints (Picture: Dr K Laubscher)

Spinal pathology

In addition to the general red flags mentioned at the beginning of the chapter, the following features may also suggest serious spinal pathology. Patients presenting with signs of cord compression or *cauda equina* syndrome (see figure below) need urgent referral to an orthopaedic or neurosurgical service.



The *cauda equina* is usually located below L3 (Picture: Dr K Laubscher)

Red flags for spinal disorders	
History	<ul style="list-style-type: none"> - Back pain in a patient < 20 or > 55 years of age. - Previous history of cancer - Immunosuppression - Thoracic pain - Pain at rest or at night - Neurological fallout - Structural deformity
Cord compression	<p>Upper motor neuron symptoms:</p> <ul style="list-style-type: none"> - Increased muscle tone - Brisk reflexes - Clonus - Weakness
Cauda equina	<p>Lower motor neuron symptoms:</p> <ul style="list-style-type: none"> - Sphincter disturbance, bladder or bowel changes, - gait abnormalities, saddle anaesthesia, sexual dysfunction, decreased tone or weakness of lower limbs, absent reflexes, diminished or absent anal wink test and a bulbocavernosus reflex

Fat embolism syndrome

Definition: Fat embolism is a rare, non-thrombotic embolism that is potentially fatal and has a mortality rate of 15%. It is a systemic dysfunction caused by the entry of fat into the circulation, most commonly from the bone marrow. The mechanism of entry into the systemic circulation is thought to be due to either a *patent foramen ovale* or via microembolism, where the fat particles are small enough to pass from the pulmonary arteries into the pulmonary veins. Patients typically develop fat embolism as a result of long bone fracture or orthopaedic surgery. It occurs 12 hours to 2 weeks following trauma or surgery. The diagnostic criteria in the following table can be used.

Management: Supportive treatment with frequent ICU admission is required.

Clinical features of fat embolism

Gurd and Wilson criteria:
2 major or 1 major and 4 minor criteria = FES

Major

- 1) Petechial rash
- 2) Respiratory symptoms plus bilateral signs with positive radiographic changes
- 3) Cerebral signs unrelated to head injury or any other condition

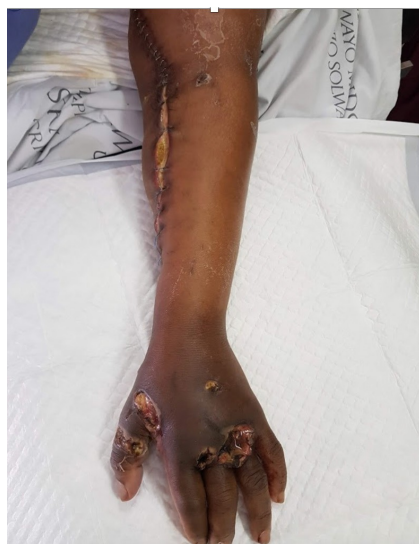Minor

- 1) Tachycardia
- 2) Pyrexia
- 3) Retinal changes (fat or petechiae)
- 4) Urinary changes (anuria, oliguria, fat globules)
- 5) Sudden drop in haemoglobin level
- 6) Sudden thrombocytopaenia
- 7) High erythrocyte sedimentation rate
- 8) Fat globules in the sputum

The leg's anterior compartment is most frequently affected (e.g. after tibia fracture), but any compartment can be affected (e.g. hand or forearm).

Early symptoms include **pain**, **paraesthesia** and swelling. Often the pain is out of proportion to what is expected from the injury. These symptoms occur as venous pressure is exceeded. Late symptoms include the other Ps: **paralysis**, absent **pulses**, **pallor** and **poikilothermia** (or cold peripheries). These symptoms occur as arterial pressure is exceeded.

The diagnosis is clinical; the management is urgent fasciotomy.



Clinical picture of a forearm with multiple gunshot injuries and fasciotomy incisions. The dusky hand indicates compromised perfusion. (Picture: Dr K Laubscher)

Compartment syndrome

Compartment syndrome results from increasing pressure in an anatomical compartment

(typically muscle compartments divided by strong fascia), where the tissue pressure exceeds the vascular perfusion pressure.

The tissue becomes ischaemic and infarction will occur without urgent intervention.

Clinical features:

Can occur after any form of injury, but most commonly associated with long bone fractures or other forms of trauma

Deep vein thrombosis

Deep vein thrombosis (DVT) occurs when there is thrombus formation in one of the deep veins, typically of the lower limb or pelvis. Thromboembolism to the pulmonary vasculature (pulmonary embolism) is the most feared complication and is potentially fatal. Importantly, Orthopaedic post-surgical patients are at a greater risk of DVT due to the nature of the operation (hip and pelvic surgery, for example) and because these patients are often older and immobile.

Clinical features:

- Unilateral leg swelling with or without associated erythema and distended superficial veins
- Pain (often worse on dorsiflexion of the foot)
- Warmth and tenderness on palpation
- Shortness of breath, chest pain, or both in pulmonary embolism cases (always look for a DVT in patients who develop respiratory symptoms in the ward).

Diagnosis: Compression ultrasonography

Management: DVTs can mostly be prevented with early mobilisation, compression stockings and pharmacological prophylaxis. Treatment involves anticoagulation therapy with heparin and warfarin.

Non-accidental injury in a child

The red flags listed at the beginning of this chapter should also be applied to children. Every child with a painful or swollen joint should be assessed as to whether they appear systemically unwell or not, and the

degree to which they can weight bear or use the affected limb. Orthopaedic and non-orthopaedic red flags are listed in the table below.

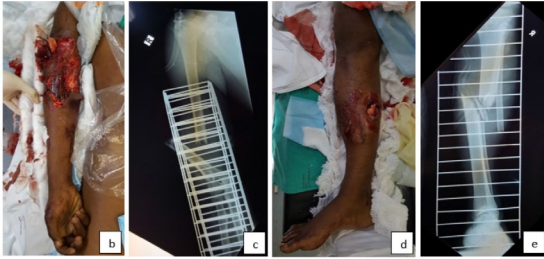Management

Clear, accurate and thorough documentation of all findings, which may also include sketches. By law, all suspected child abuse must be reported to the relevant authorities (police, social worker, and so on). See the specific chapter in the section on fractures in children for an approach to these patients.

Red flags for child abuse
<ul style="list-style-type: none">- Multiple fractures at different stages of healing.- Fractures other than the skull or clavicle in neonates (may occur during birth).- Severe skull fractures in children under 18 months.- Long bone fractures in infants not yet walking.- Digital fractures in children under three years.- Sternal, rib or scapula fractures (suggest high energy force).- Vertebral body fractures.- Metaphyseal corner fractures (occurs when a limb is pulled, twisted or shaken).- Epiphyseal separations.
<ul style="list-style-type: none">- Inconsistent history, lack of witnesses for the incident or clinical findings inconsistent with the reported mechanism of injury.

Open fractures

Irrigate, stabilise and administer appropriate early antibiotics. See the chapter on 'Orthopaedic Injuries'.



Clinical and radiological images of open fractures (Picture: Dr K Laubscher)

References

Amboss. Nonthrombotic embolism, 2019.
Available: <https://www.amboss.com/us/>

Department of Health. Standard
Treatment Guidelines and Essential
Medicines List for South Africa.
(Cellphone application, most
recently updated 2019)

Kearon C, Bauer KA, 2018.
Clinical presentation and diagnosis
of the nonpregnant adult with
suspected deep vein thrombosis of
the lower extremity. Available
[Online in UpToDate]: [https://
www.uptodate.com/contents/clinic
al- presentation-and-diagnosis-of-
the- nonpregnant-adult-with-
suspected-deep- vein-thrombosis-
of-the-lower-extremity](https://www.uptodate.com/contents/clinical-presentation-and-diagnosis-of-the-nonpregnant-adult-with-suspected-deep-vein-thrombosis-of-the-lower-extremity)

Luqmani R, Joseph B, Robb J, Porter D.
Textbook of orthopaedics, trauma and
rheumatology. Elsevier Health Sciences,
Dec 20, 2012.

Rasul AT, 2018. Acute compartment
syndrome. Available:
[https://emedicine.
medscape.com/article/307668-
overview#a3](https://emedicine.medscape.com/article/307668-overview#a3)

Scherl SA, 2019. Orthopedic
aspects of child abuse.
Available [Online in
UpToDate]:
[https://www.uptodate.com/co
ntents/ orthopedic-aspects-
of-child-abuse](https://www.uptodate.com/contents/orthopedic-aspects-of-child-abuse)

Stracciolini A, Hammerberg EM,
2018. Acute compartment syndrome
of the extremities. Available [Online
in
UpToDate]: [https://www.uptodate.com/
contents/acute-compartment-syndrome-
of- the-extremities](https://www.uptodate.com/contents/acute-compartment-syndrome-of-the-extremities)

Weinhouse G, 2019. Fat
embolism syndrome.
Available [Online in
UpToDate]:
[https://www.uptodate.com/
contents/fat-embolism-
syndrome](https://www.uptodate.com/contents/fat-embolism-syndrome)

Editor: Michael Held

Conceptualisation: Maritz Laubscher & Robert Dunn

Cover design: Carlene Venter
(Creative Waves Brand Design)

Developmental editing and design:
Vela Njisane and Phinda Njisane

ABOUT THE BOOK

Informed by experts: Most patients with orthopaedic pathology in low to middle-income countries are treated by non-specialists. This book was based on a modified Delphi consensus study* with experts from Africa, Europe, and North America to provide guidance to these health care workers. Knowledge topics, skills, and cases concerning orthopaedic trauma and infection were prioritised. Acute primary care for fractures and dislocations ranked high.

Furthermore, the diagnosis and the treatment of conditions not requiring specialist referral were prioritised.

* Held et al. Topics, Skills, and Cases for an Undergraduate Musculoskeletal Curriculum in Southern Africa: A Consensus from Local and International Experts. JBJS. 2020 Feb 5;102(3):e10.

THE LION

The Learning Innovation via Orthopaedic Network (LION) aims to improve learning and teaching in orthopaedics in Southern Africa and around the world. These authors have contributed the individual chapters and are mostly orthopaedic surgeons and trainees in Southern Africa who have experience with local orthopaedic pathology and treatment modalities but also in medical education of undergraduate students and primary care physicians. To centre this book around our students, iterative rounds of revising and updating the individual chapters are ongoing, to eliminate expert blind spots and create transformation of knowledge.

DISCLAIMERS

Although the authors, editor and publisher of this book have made every effort to ensure that the information provided was correct at press time, they do not assume and hereby disclaim any liability to any party for any loss, damage, or disruption caused by errors or omissions, whether such errors or omissions result from negligence, accident, or any other cause.

This textbook is not intended as a substitute for the medical advice of physicians. The reader should regularly consult a physician in matters relating to his/her health and particularly with respect to any symptoms that may require diagnosis or medical attention.

The information in this book is meant to supplement, not replace, Orthopaedic primary care training. The authors, editor and publisher advise readers to take full responsibility for their safety and know their limits. Before practicing the skills described in this book, be sure that your equipment is well maintained, and do not take risks beyond your level of experience, aptitude, training, and comfort level.

The individual authors of each chapter are responsible for consent and rights to use and publish images in this book.

© The Authors 2021



Licensed under a Creative Commons Attribution (CC BY) 4.0 International Licence.

ACKNOWLEDGEMENTS

This work was carried out with the aid of a grant from the International Development Research Centre, Ottawa, Canada. Thanks to Johan Fagan, Michelle Willmers and Glenda Cox for their mentorship and support.