

Subtotal petrosectomy involves *complete exenteration of all air cells of the temporal bone (middle ear and mastoid)*. It includes the following cell tracts: retrosigmoid, retrofacial, antral, retrolabyrinthine, supralabyrinthine, infralabyrinthine, supratubal and pericarotid cells. Only a few cells in the petrous apex are left behind. The otic capsule is either kept intact or removed (subtotal petrosectomy with or without removal of the otic capsule). The external auditory canal is closed as a blind sac and the cavity obliterated with abdominal fat and a temporalis muscle flap. Complete removal of disease is important before obliterating the cavity

Indications

- Chronic otitis media when there is no possibility of hearing reconstruction, and one wishes to attain a dry, safe ear (*Figure 1*)
- Chronic otitis media in a completely deaf ear (*Figure 2*)
- Middle ear tumours (*Figure 3*)
- CSF leaks which may be traumatic, iatrogenic or (rarely) spontaneous
- Supralabyrinthine and/or infralabyrinthine cholesteatoma
- Transverse temporal bone fracture (*Figure 4*)
- In combination with another neurotologic procedure *e.g.* Transotic and Infratemporal fossa approaches “Types A, B or C”
- Cochlear or middle ear implantations where an open cavity has previously been performed (*Figure 5*)
- Cochlear implantation in the case of congenital cochlear dysplasia where there is a high risk of a CSF gusher
- Osteoradionecrosis of the temporal bone

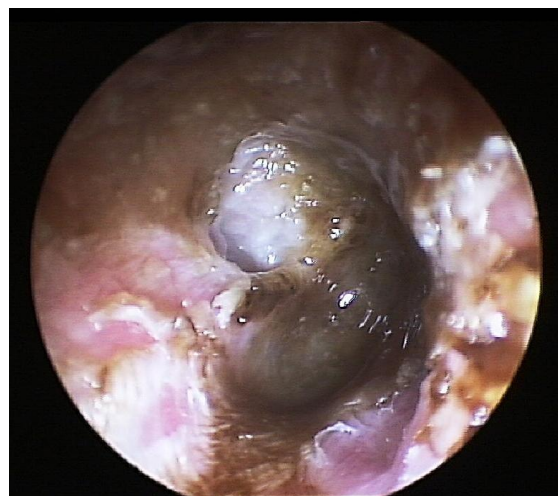

Figure 1: Chronically discharging mastoid cavity

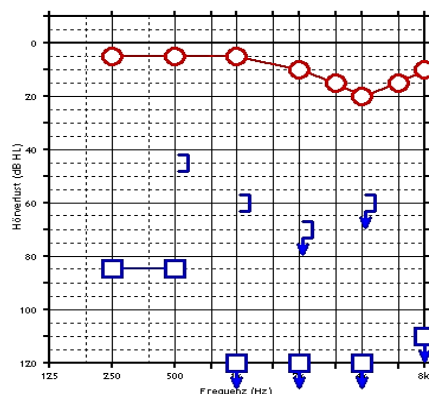


Figure 2: Audiogram showing dead left ear

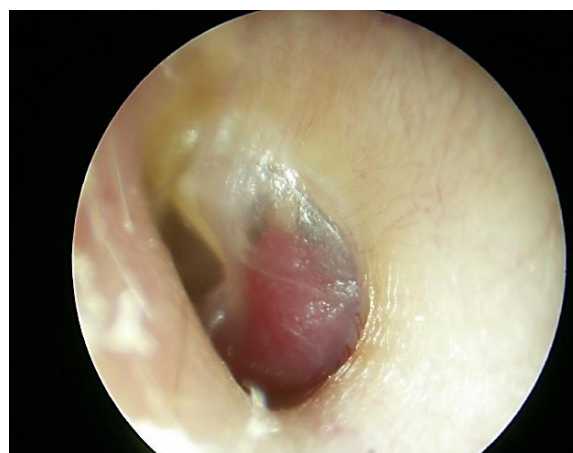

Figure 3: Type B temporal paraganglioma

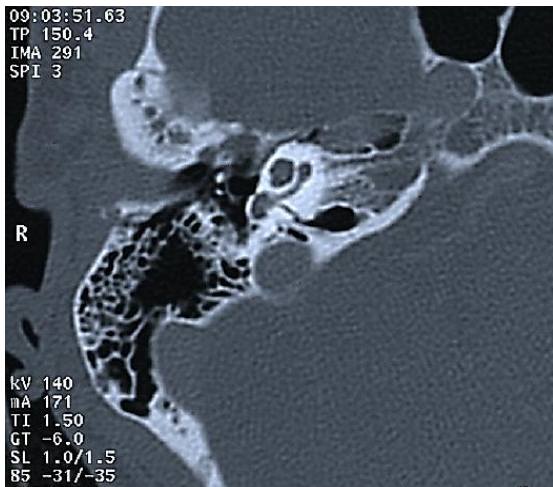

Figure 4: Transverse temporal bone fracture of right ear involving vestibule

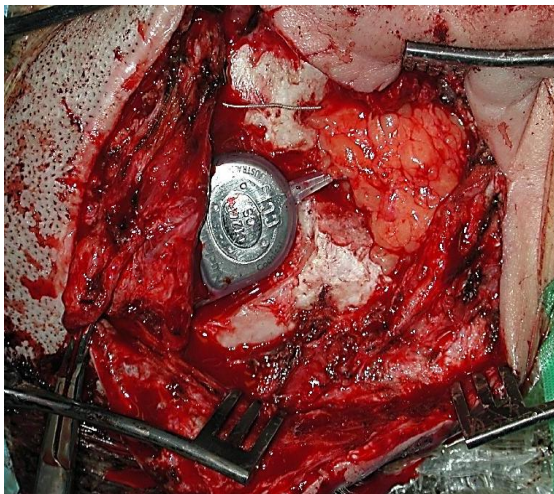


Figure 5: Subtotal petrosectomy and cochlear implant

Preoperative management

Imaging

- Patients undergoing subtotal petrosectomy require High-Resolution CT (HRCT) scan prior to surgery
- Refer to the preoperative CT checklist in the chapter on [Mastoidectomy and epitympanectomy](#)
- If patients have had previous surgery, it is particularly important to pay attention to structures which may have been exposed at the primary surgery e.g. facial nerve, sigmoid sinus and dura

Audiogram

- Review audiograms to decide whether it is necessary to remove the stapes superstructure or if it should be preserved
- If there is no possibility of hearing reconstruction e.g. a dead ear, then the stapes superstructure may be removed
- If hearing is reasonable then it may be wise to preserve the stapes superstructure as the patient may decide to have a semi-implantable hearing aid (*Vibrant Soundbridge*) fitted in the future.

Perioperative antibiotics: Amoxicillin with clavulanic acid

Operative site

- The patient's hair is shaved for 7cm above and behind the hairline
- The inferior abdominal quadrant and suprapubic areas are shaved and prepared for harvesting a fat graft

Positioning: The patient lies supine with the head turned away from the surgeon (*Figure 6*)

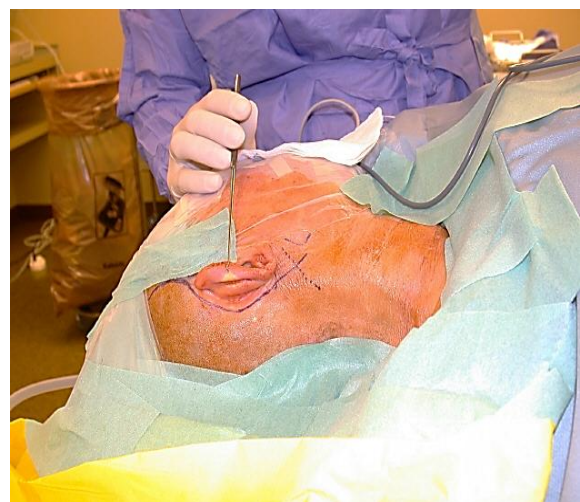

Figure 6: Positioning of patient

Facial nerve monitoring: Avoid long-acting muscle relaxants as the facial nerve should be monitored intraoperatively

Surgical Steps

Skin Incision

- A postauricular S-shaped incision is made from the temporal region to 1cm below the mastoid tip (*Figure 7*)
- The superior part of the incision above the temporal line is only made at the end of the procedure when a temporalis muscle flap is needed

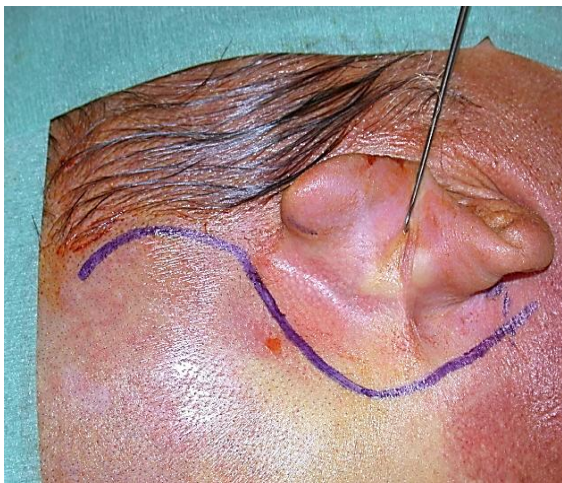

Figure 7: Postauricular S-shaped incision

Mastoid periosteal flap

- This flap is used as a 2nd layer in the closure of the external auditory canal and is therefore left attached to the cartilaginous canal
- Using a surgical scalpel with a # 10 blade, the skin is reflected anteriorly remaining superficial to temporalis fascia and muscle
- The anteriorly based periosteal flap is developed measuring about the size of the surgeon's finger (*Figure 8*)
- It must be long enough to achieve closure of the external canal especially in the case of previous surgery with an open cavity where the periosteal tissue may be of poor quality

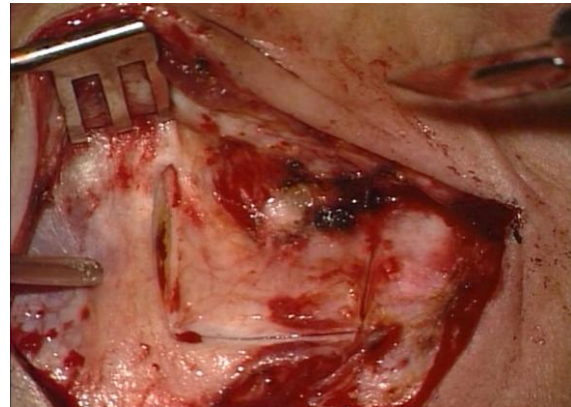

Figure 8: Mastoid periosteal flap

Blind sac closure of external auditory canal

Transection of the auditory canal

- The periosteal flap is elevated until the bony-cartilaginous junction of the external auditory canal is reached
- An incision is made from 6-12 o'clock in the posterior auditory canal (*Figure 9*)

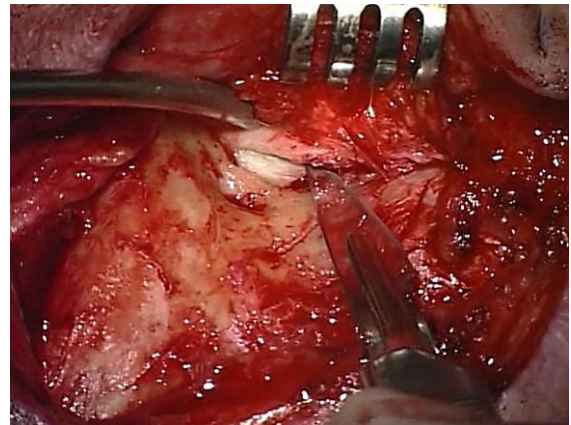


Figure 9: Incision in ear canal

- To transect the anterior portion of the canal, use a curved clamp to find the tragal cartilage
- A large, curved artery clamp is then used to develop a plane anterior to the tragal cartilage separating the parotid from the cartilage

- Holding the curved clamp in this position, a # 15 blade is used to safely transect the anterior canal by cutting onto the curved clamp. This avoids injury to the facial nerve (*Figure 10*)

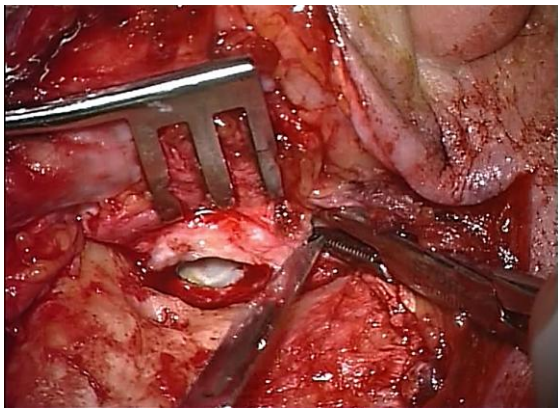


Figure 10: Safely transecting anterior wall of ear canal

Eversion of auditory canal skin

- Ocular magnifying loupes are useful for this step
- The skin of the cartilaginous canal is elevated for 1cm from the cut margin with tympanoplasty scissors to facilitate eversion of the canal (*Figure 11*)

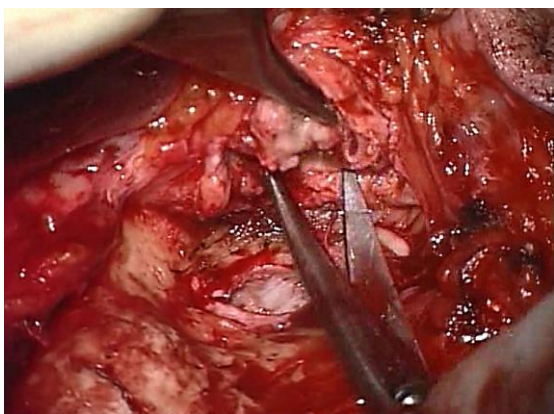


Figure 11: Elevating skin of external canal

- It is important that the skin of the external canal is not breached. To avoid this, direct the curve of the tympanoplasty scissors towards the cartilage

- It may be difficult to find the correct plane, especially if a previous open mastoidectomy with a wide meatoplasty was performed
- Two 2-0 Vicryl stay sutures are placed at 6 and 12 o'clock. These are placed as 2 purse string sutures with the free ends on the inside of the canal (*Figures 12, 13*)

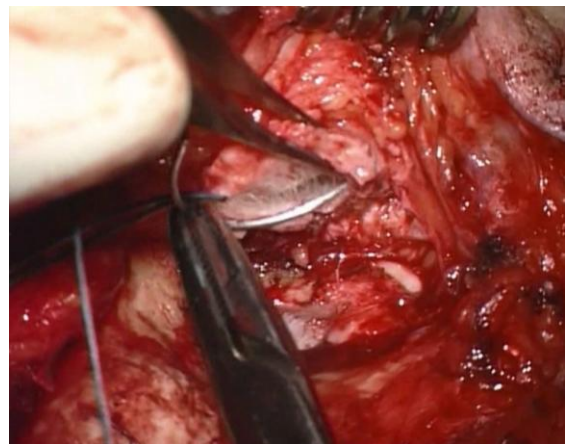

Figure 12: Placing stay sutures

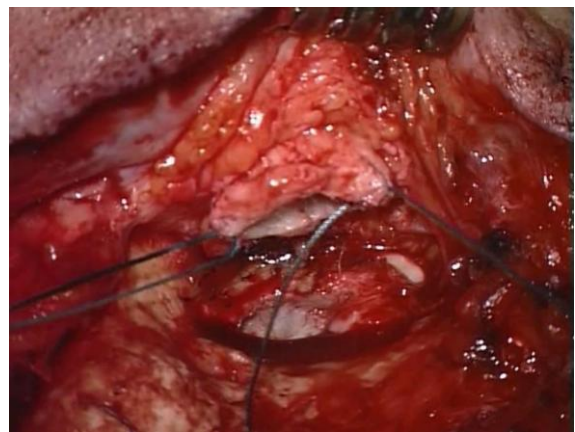

Figure 13: Stay sutures

- A curved artery clamp is passed through the canal from externally and applied to each of the free ends of the two stay sutures. Tension is applied to the stay sutures to evert the canal skin (*Figure 14*)
- The tragus is retracted with a skin hook and the skin edges are oversewn with 4-0 Vicryl suture (*Figures 15, 16*)

- The periosteal flap is folded back as a 2nd layer to the blind sac closure of the external auditory canal (*Figure 17*). It is sutured to the cartilage of the external auditory canal with 2-0 Vicryl

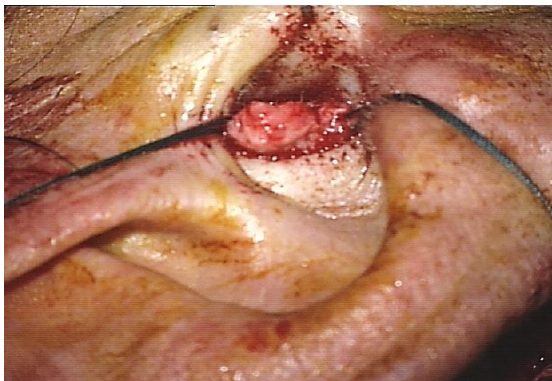

Figure 14: Everting skin of the ear canal

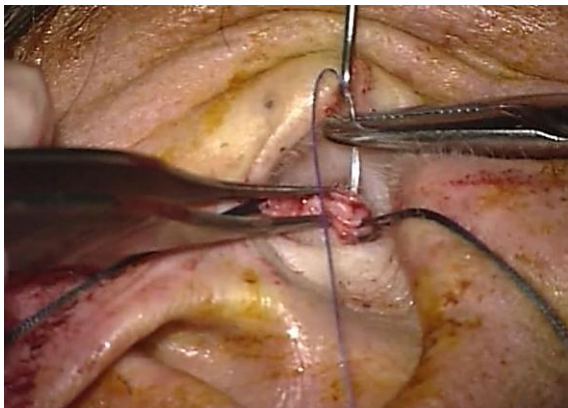


Figure 15: Oversewing canal

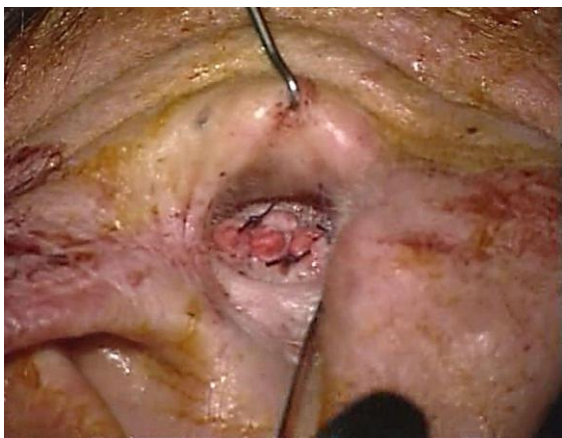


Figure 16: Oversewn canal

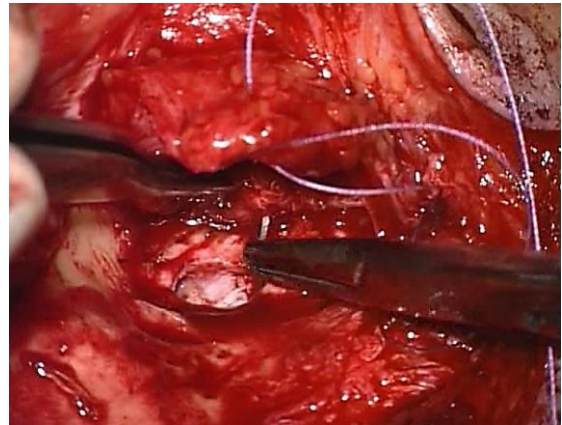


Figure 17: Oversewing the sac with the periosteal flap

Removal of lateral external auditory canal skin

- The skin of the bony external canal is elevated with a Key raspatory
- This skin cuff is removed with tympanoplasty scissors (*Figure 18*)

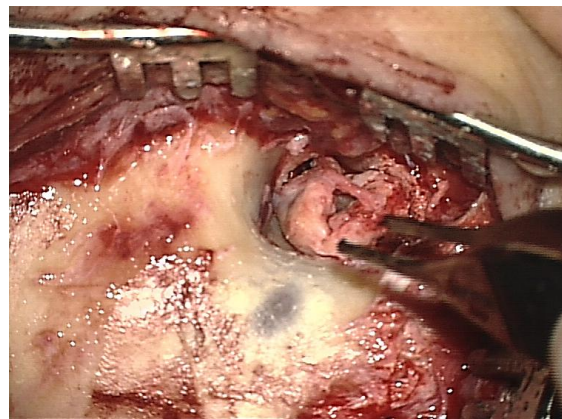


Figure 18: Removing skin of ear canal

Removal of medial external auditory canal skin

- A microraspatory and small strip of adrenaline gauze is used to elevate the remnants of the external auditory canal skin to the annulus
- The middle ear is entered at the posterior tympanic spine and the annulus is elevated. The short process of malleus,

chorda tympani and incudostapedial joint are now visible

- *Chorda tympani* is divided with a large Bellucci scissors
- The incudostapedial joint is separated with a 45° 1,5mm hook
- The malleus is cut at its neck with a malleus nipper
- *Tensor tympani* tendon is cut with a large Bellucci scissors
- The tympanic membrane (with handle of malleus attached) is now removed along with the incus and head of malleus

Mastoidectomy

- It is important that all mastoid cells are exenterated, and no mucosa is left behind as this can potentially form mucocoeles
- Structures like dura, sigmoid sinus and facial nerve must be skeletonised, not exposed
- Using a mastoid raspatory elevate the soft tissues off the mastoid
- Free the sternocleidomastoid muscle from its insertion into the mastoid tip
- Place a 2-0 silk stay suture from the edge of temporalis muscle to its fascia to expose the area above the temporal
- Next proceed as for open mastoidoepi-tympanectomy (see [chapter on mastoidectomy](#))
- It is important that all mastoid cells are exenterated, and no mucosa is left behind as this can potentially form mucocoeles
- Structures like dura, sigmoid sinus and facial nerve must be skeletonised, not exposed
- Using a mastoid raspatory elevate the soft tissues off the mastoid
- Free the sternocleidomastoid muscle from its insertion into the mastoid tip

- Place a 2-0 silk stay suture from the edge of temporalis muscle to its fascia to expose the area above the temporal
- Next proceed as for open mastoidoepi-tympanectomy

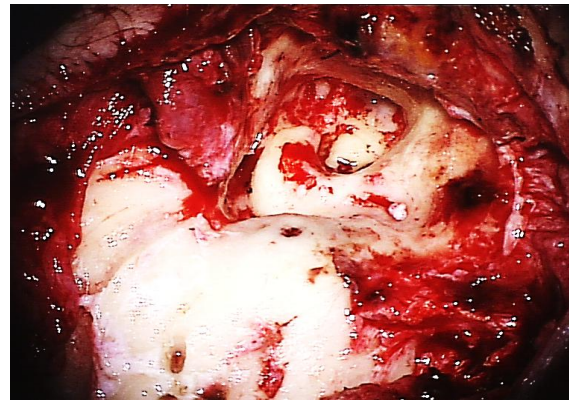


Figure 19: Mastoid cavity with all cell tracts having been exenterated

Technical points

- When drilling in the supralabyrinthine segment a diamond drill is used in reverse when operating on the right ear to avoid injuring the facial nerve
- The mucosa of the middle ear can be removed by using the microraspatory and scraping the mucosa with a small cotton ball, taking care not to sublax the stapes superstructure if left intact

Obliteration of Eustachian tube

- The internal carotid artery is followed superiorly to the medial wall of the Eustachian tube (watch out for a dehiscent carotid at this point!)
- The mucosa of the bony Eustachian tube is removed as far as the isthmus with a 2mm/3mm diamond burr
- At this point the remaining mucosa is coagulated with bipolar forceps and the Eustachian tube is obliterated with bone wax (*Figure 20*)

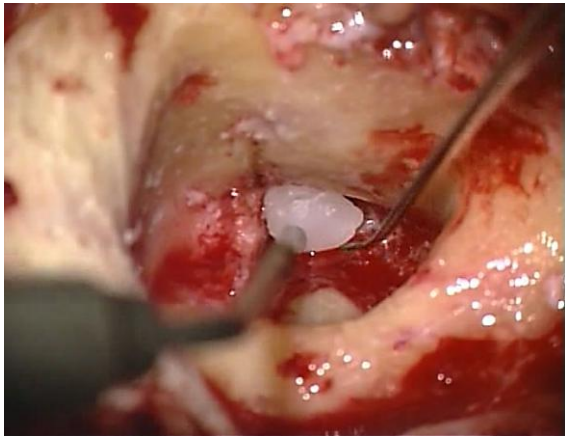


Figura 20: Eustachian tube obliterated with bone wax

- Using a cottonoid, the bone wax may be pushed into the orifice of the Eustachian tube with a suction tip. The tip of the microraspatory is directed away from the carotid (*Figure 21*)
- A temporalis muscle musculofascial graft is used as an additional seal of the orifice by placing it lateral to the bone wax

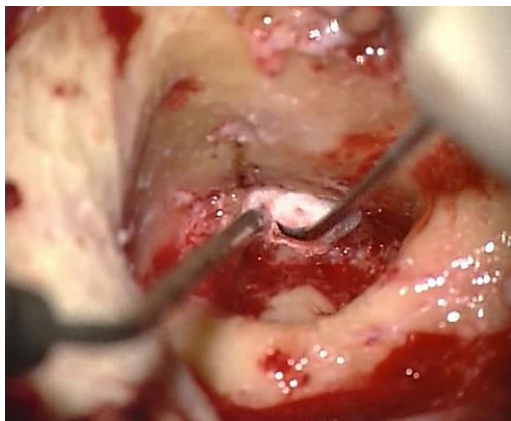


Figure 21: Eustachian tube obliterated with bone wax

Technical points

- The tensor tympani muscle can be dissected out of its semicanal by drilling its lateral surface and reflecting it anteriorly with a microraspatory into the protympanum and the Eustachian tube orifice

- Bone wax is then placed over this so that the muscle lies sandwiched between two layers of bone wax, thus obliterating the Eustachian tube

Obliteration of Operative Cavity

- The middle ear cleft is obliterated with abdominal fat harvested from the lower quadrant of the abdomen (*Figure 22*)

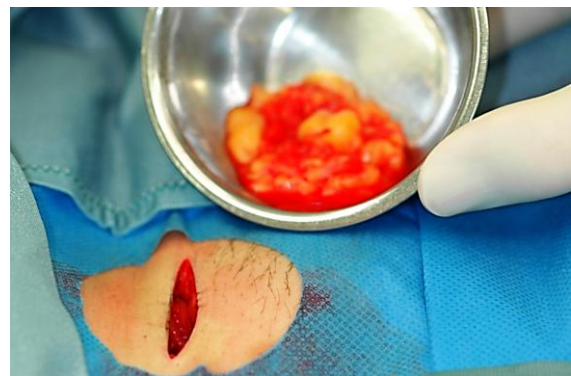

Figura 22: Grasa abdominal

- It is important to achieve meticulous haemostasis as a haematoma of the abdominal wound is the most common complication of subtotal petrosectomy
- Place a suction drain in the abdominal wound
- The abdominal wound is closed in layers using subcutaneous 3-0 Vicryl and Monocryl 3-0 or nylon 3-0 to skin
- With osteoradionecrosis of the temporal or chronic infection it is advisable not to use abdominal fat to obliterate the cavity; rather use only temporalis muscle

Transposition of temporalis muscle

- The skin incision is extended superiorly above the temporal line to expose the temporalis muscle
- Remaining in a plane above the temporalis fascia, the skin and soft tissue edges are undermined

- The assistant retracts the skin edges with two skin rakes, for exposure
- The posterior 2/3 of the temporalis muscle is mobilised by creating a flap using a diathermy knife
- To facilitate mobilisation and transposition of the temporalis flap over the mastoid cavity, a small, inverted V-shaped incision is made at the base of the temporalis muscle
- The muscle flap is rotated inferiorly over the cavity and sutured to the sternocleidomastoid muscle and soft tissues of the occiput with 2-0 Vicryl (*Figure 23*)
- Inevitably the fat used to obliterate the cavity will atrophy; therefore, more fat is placed in the cavity once the temporalis muscle has been sutured to the soft tissues via the superior pocket created by the transposed temporalis flap (*Figure 24*)

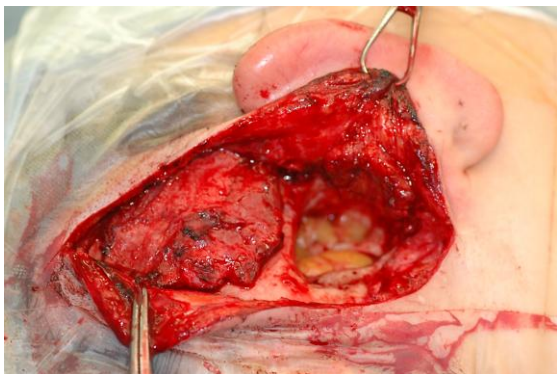


Figure 23: Temporalis flap and abdominal fat in petrossectomy defect

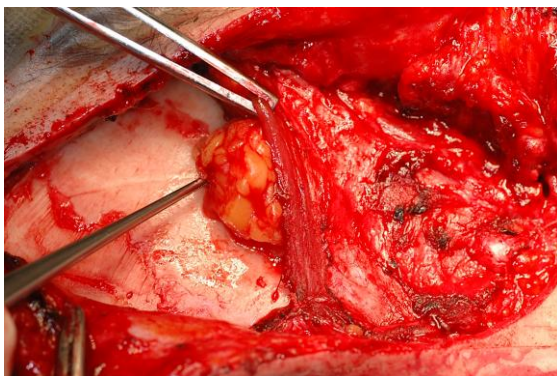


Figure 24: Additional fat placed in defect

Wound Closure

- A 3mm suction drain is placed under the scalp over the squamous part of the temporal bone and not over the mastoid cavity
- The wound is closed in layers with 2-0 Vicryl sutures subcutaneously and skin clips
- A compression bandage is applied

Postoperative care

- Antibiotics (amoxicillin with clavulanic acid) are continued for one week post-operatively
- The drain is left in place until the drainage is less than 10mls/24hrs
- If the surgery was done for a CSF leak, then the drain is removed on the first postoperative day
- The abdominal drain is removed when the drainage is less than 10mls/24hrs
- Clips/sutures are removed after 10 days
- The resorbable Vicryl sutures within the external ear canal are removed at 4 weeks

Long-term follow-up

Imaging

- Where subtotal petrossectomy is performed for chronic otitis media, CT scans are routinely performed after one year and then again at 3 years
- In cases of previous cholesteatoma, a diffusion weighted non-EPI MRI would detect recurrent disease

Auditory rehabilitation

This depends on the status of hearing of opposite ear, the degree and type of hearing loss and cochlear function. The options are a bone anchored hearing aid (BAHA) if the inner ear function has been preserved of the ipsilateral or contralateral ear; active

middle ear implant (e.g. *Vibrant Soundbridge*) where there is good cochlear reserve; or a cochlear implant (bilateral deafness).

References

1. Fisch U, Mattox D, eds. *Microsurgery of the Skull Base*. Stuttgart, Germany: Georg Thieme Verlag, 1988.
2. Linder T, Schlegel C, DeMin N, van der Westhuizen S. Active Middle Ear Implants in Patients Undergoing Subtotal Petrosectomy: New Application for the Vibrant Soundbridge Device and Its Implication for Lateral Cranium Base Surgery. *Otol Neurotol*. 2008; 30:41-7

Acknowledgements

This guide is based on the text by Professor Fisch (*Microsurgery of the Skull Base*) and personal experience of Professor Linder, as well as course materials for the lateral skull base course conducted annually by Professors Fisch and Linder at the Department of Anatomy, University of Zurich, Switzerland.

How to cite this chapter

Harris T, Linder T. (2017). Subtotal petrosectomy. In *The Open Access Atlas of Otolaryngology, Head & Neck Operative Surgery*. Retrieved from <https://vula.uct.ac.za/access/content/group/ba5fb1bd-be95-48e5-81be-586fbaeba29d/Subtotal%20petrosectomy.pdf>

Authors

Tashneem Harris MBChB, FCORL, MMed (Otol)
Fisch Instrument Microsurgical Fellow
Associate Professor and ENT Specialist
Division of Otolaryngology
University of Cape Town
Cape Town, South Africa
harristasneem@yahoo.com

Thomas Linder, M.D.
Professor, Chairman and Head of Department of Otorhinolaryngology,
Head, Neck and Facial Plastic Surgery
Lucerne Canton Hospital, Switzerland
thomas.linder@ksl.ch

Editor

Johan Fagan MBChB, FCS (ORL), MMed Emeritus Professor and Past Chair
Division of Otolaryngology
University of Cape Town
Cape Town, South Africa
johannes.fagan@uct.ac.za

**THE OPEN ACCESS ATLAS OF
OTOLARYNGOLOGY, HEAD &
NECK OPERATIVE SURGERY**
www.entdev.uct.ac.za



The Open Access Atlas of Otolaryngology, Head & Neck Operative Surgery by [Johan Fagan \(Editor\) johannes.fagan@uct.ac.za](mailto:johannes.fagan@uct.ac.za) is licensed under a [Creative Commons Attribution - Non-Commercial 3.0 Unported License](https://creativecommons.org/licenses/by-nc/3.0/)

