



Adenoidectomy may be done in isolation or combined with tonsillectomy. Adenoidectomy may be either *total* or *partial*. *Partial adenoidectomy* involves leaving a ridge of adenoidal tissue inferiorly in the area of *Passavant's ridge* to enable apposition of the soft palate to the posterior pharyngeal wall during swallowing; it is indicated when there is concern about causing velopharyngeal insufficiency (VPI) *e.g.* with a submucous cleft palate.

Indications

Adenoidectomy is frequently combined with tonsillectomy and/or insertion of grommets. Other indications include:

- Obstructive sleep apnoea
- Nasal obstruction
- Problematic rhinorrhoea
- Recurrent upper respiratory tract infection
- Recurrent acute otitis media
- Recurrent otitis media with effusion
- For histological analysis

History and Clinical Examination

Adenoidal hypertrophy presents with nasal obstruction, mouth breathing, rhinorrhoea, snoring and sleep apnoea. *Recurrent adenoiditis* may manifest with otitis media with effusion (glue ear) with or without hearing loss, recurrent acute otitis media, rhinorrhoea and recurrent upper respiratory tract infections.

Clinically, adenoid size can only be accurately determined in the awake patient by fiberoptic nasendoscopy. Occasionally, enlarged adenoids can be seen extending below the soft palate, or at the back of a well-decongested nasal cavity using an otoscope. Nasal airflow can be determined by placing a metal spatula under the nose and

looking for “misting” on expiration; enlarged adenoids are associated with reduced “misting”.

Before embarking on surgery, the following points need to be elicited on history and examination

- Bleeding diathesis
- Obstructive sleep apnoea: avoid perioperative sedation and monitor carefully for apnoea postoperatively
- Previous cleft palate repair: total adenoidectomy may cause velopharyngeal insufficiency

Surgical anatomy

The adenoid is situated in the midline of the posterior nasopharyngeal wall immediately below the rostrum of the sphenoid. It constitutes the superior portion of pharyngeal lymphoid tissue termed *Waldeyer's ring*. The nasopharynx communicates with the nasal cavity via the posterior choanae. The adenoids can enlarge to obstruct the choanae causing nasal obstruction and rhinorrhoea (*Figure 1*).

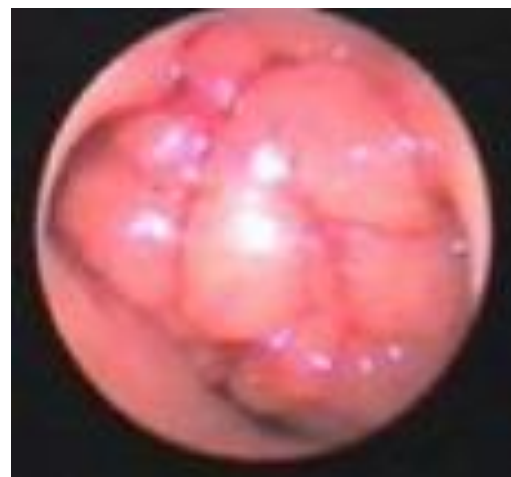

Figure 1: Enlarged adenoids obstructing posterior choana

The space lateral to the adenoid and posteromedial to the orifice of the Eustachian tube is termed the *fossa of Rosenmüller*. *Gerlach's tonsil* refers to a collection of lymphoid tissue located within the lip of the *fossa of Rosenmüller* and can extend into the Eustachian tube. Inferiorly, the adenoids abut the upper margin of the superior constrictor or *Passavant's ridge* (Figure 2).

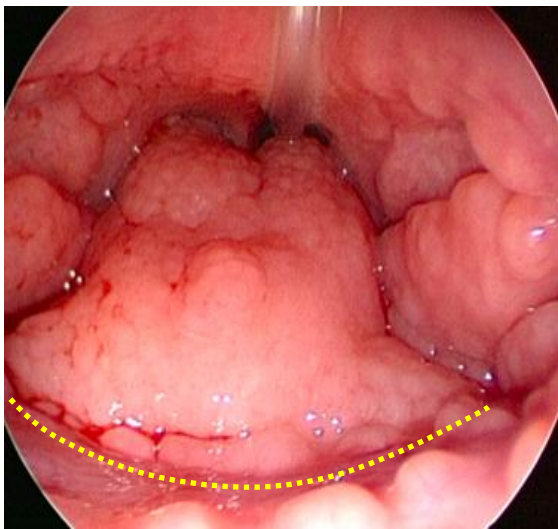


Figure 2: View from below of adenoids extending superiorly from Passavant's ridge (broken yellow line)

The **arterial blood supply** to the adenoid arises from branches of the external carotid artery *i.e.* ascending pharyngeal, ascending palatine, pharyngeal branch of maxillary artery, sphenopalatine, and artery of the pterygoid canal. **Venous drainage** is to the facial and internal jugular systems. **Sensory innervation** is provided by the glossopharyngeal (IX) and vagus (X) nerves; this explains the referred pain that patients experience to the ear and throat with adenoid infection and following adenoidectomy.

Grading of adenoid size

The percentage of choanal obstruction is often used to grade the size of adenoids (Table 1). This is best achieved by flexible nasendoscopy in an awake patient (if pos-

sible) or with a dental mirror placed in the postnasal space in an anaesthetised patient.

Grade	Choanal obstruction
1	< 1/3
2	1/3 - 2/3
3	2/3 - 3/3

Table 1: Grading system for adenoid size

Surgical equipment

An adenoid curette and/or suction diathermy are commonly used to perform adenoidectomy. Advantages of suction diathermy include targeted, directed removal of the adenoids avoiding injury to adjacent structures, clearing choanal adenoidal tissue and haemostasis. Figures 3-5 illustrate the equipment required to perform adenoidectomy with a curette and with suction diathermy.

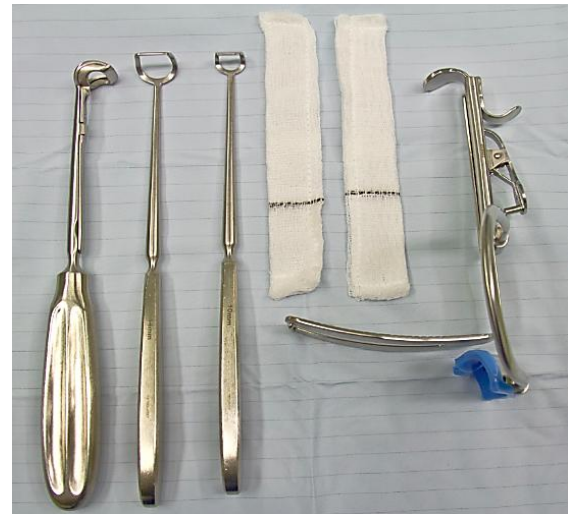

Figure 3: Instruments used to perform curette adenoidectomy: curettes, Boyle-Davis gag and tonsil swabs




Figure 4: Drafton rods are used to suspend the Boyle Davis gag and stabilize the head

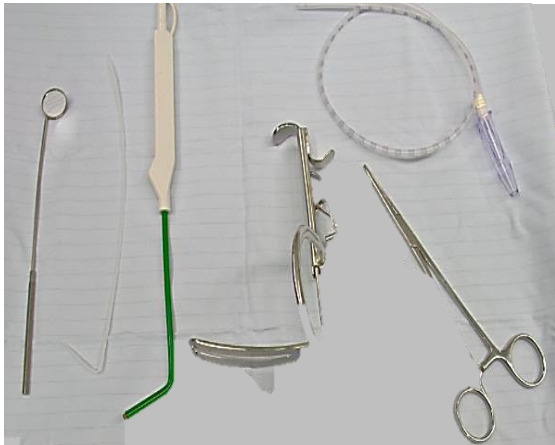

Figure 5: Instruments to perform adenoidectomy with suction diathermy: monopolar suction diathermy, Boyle-Davis gag, dental mirror, Burkitt straight forceps and suction catheter

Preliminary steps

- General anaesthesia with endotracheal intubation using an angled tube or with a laryngeal mask
- Position the patient supine with a shoulder roll to achieve extension of the neck
- Insert a *Boyle Davis mouth gag*; ensure that the ventilation tube and tongue are in the midline (*Figures 3, 4, 6*)
- Open the gag to expose the oropharynx
- Stabilise the patient's head in the desired position by inserting *Drafton suspension rods* (*Figures 4, 6*)
- To improve the view of the nasopharynx, insert a nasal catheter in one/both nostrils and bring it out through the mouth; secure both ends with an artery clip to retract the soft palate anteriorly (*Figure 7*)
- Assess the size of the adenoids and exclude an aberrant or dehiscent internal carotid artery by examining the nasopharynx with a dental mirror and/or by digital palpation
- Palpate the palate to exclude an occult submucous cleft palate; proceeding

with adenoidectomy in such cases can cause *rhinolalia aperta*

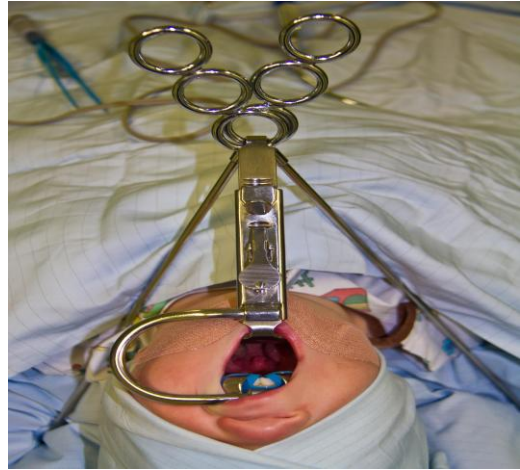

Figure 6: Boyle Davis gag suspended and held in place with Drafton rods

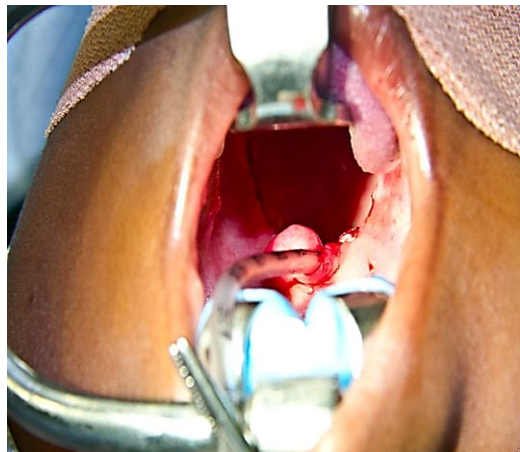

Figure 7: Note nasal catheter retracting soft palate anteriorly

Curette Adenoidectomy

- Use the largest adenoidectomy curette that will engage the adenoids
- A dental mirror aids the surgeon to place the curette under direct vision
- Stabilise the head with the non-dominant hand
- Remove the adenoids with a firm, single scraping motion from superiorly to inferiorly
- Inspect the adenoid bed to assess whether removal is complete; if not, repeat

the process until complete removal has been achieved

- Place swabs/sponges in the postnasal space while continuing with the tonsillectomy if indicated
- Remove the swabs after a few minutes
- Confirm haemostasis by inspecting the nasopharynx with a mirror
- Haemostasis can be achieved by using monopolar suction diathermy; it is absolutely essential that there is complete haemostasis
- Remove all clots from the nose and nasopharynx with a suction catheter passed through the nose
- Document in the surgical notes that haemostasis has been achieved and clots cleared

Suction Diathermy Adenoidectomy

- Bend the tip of the suction diathermy to 90 degrees with the introducer still in place to prevent kinking and occlusion of its lumen (*Figure 8*)
- Remove the introducer and connect continuous suction
- Set the monopolar diathermy at 38 Watts
- With a mirror held in the non-dominant hand, pass the suction diathermy behind the palate
- Using a combination of sweeping motions and localised "spot welding", remove or ablate the adenoids under direct vision until a clear view of the posterior choanae is obtained (*Figure 9*)

Postoperative Care

Adenoidectomy is commonly performed as a day case procedure. Paracetamol is usually sufficient to control postoperative pain. If suction diathermy was used, broad spectrum antibiotics (co-amoxiclav) is administered for a week postoperatively to




Figure 8: The suction diathermy tip is bent to 90 degrees with the introducer in place to prevent complete occlusion of the lumen at the bend

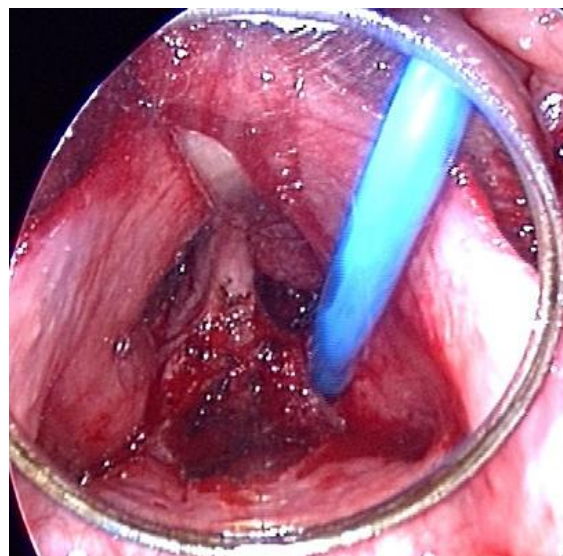


Figure 9: Suction diathermy adenoidectomy under direct vision using a mirror in the postnasal space.

treat the resulting nasal discharge. Patients are advised to miss school for 5 days and generally recover within a week.

Complications following adenoidectomy

Early

- Bleeding (more commonly with curette adenoidectomy)
- Aspiration of retained blood clot causing acute airway obstruction (*Coronor's clot*)

Late

- Nasal discharge (suction diathermy)
- *Grisel syndrome* (atlanto-axial instability)
- Scarring of Eustachian tube opening causing middle ear dysfunction
- Nasopharyngeal stenosis
- Velopharyngeal insufficiency
- Regrowth of adenoids

How to cite this chapter

Jonas N. (2013). Paediatric adenoidectomy. In *The Open Access Atlas of Otolaryngology, Head & Neck Operative Surgery*. Retrieved from <https://vula.uct.ac.za/access/content/group/ba5fb1bd-be95-48e5-81be-586fbaeba29d/Paediatric%20Adenoidectomy.pdf>

Author and Paediatric Section Editor

Nico Jonas MBChB, FCORL, MMed
Paediatric Otolaryngologist
Addenbrooke's Hospital
Cambridge
United Kingdom
nico.jonas@gmail.com

Editor

Johan Fagan MBChB, FCS (ORL), MMed
Emeritus Professor and Past Chair
Division of Otolaryngology
University of Cape Town
Cape Town, South Africa
johannes.fagan@uct.ac.za

THE OPEN ACCESS ATLAS OF OTOLARYNGOLOGY, HEAD & NECK OPERATIVE SURGERY

www.entdev.uct.ac.za



The Open Access Atlas of Otolaryngology, Head & Neck Operative Surgery by [Johan Fagan \(Editor\)](mailto:johannes.fagan@uct.ac.za) johannes.fagan@uct.ac.za is licensed under a [Creative Commons Attribution - Non-Commercial 3.0 Unported License](https://creativecommons.org/licenses/by-nc/3.0/)

