

OPEN ACCESS ATLAS OF OTOLARYNGOLOGY, HEAD & NECK OPERATIVE SURGERY



MYRINGOPLASTY & TYMPANOPLASTY

Tashneem Harris & Thomas Linder

The goals myringoplasty and tympanoplasty are to achieve a dry, self-cleansing ear while preserving or restoring hearing.

Myringoplasty refers to grafting of the tympanic membrane without inspection of the ossicular chain.

Tympanoplasty entails grafting of the tympanic membrane with inspection of ossicular chain with/without reconstruction of the middle ear hearing mechanism.

Ossiculoplasty is reconstruction of the hearing mechanism using either an autologous graft or prosthesis.

Meatoplasty involves enlargement of the lateral cartilaginous portion of the external auditory canal. A narrow entrance to the ear canal within the cartilaginous portion of the canal prevents proper ventilation and self-cleaning of the ear canal and may compromise hearing aid fitting.

([Meatoplasty video](#))

Canalplasty is partial or total widening of the bony portion of the external ear canal. In order to visualise the tympanic annulus, particularly in anterior or subtotal perforations, canalplasty is essential and may be an integral part of myringoplasty or tympanoplasty. ([Canalplasty video](#))

Preoperative assessment

Otomicroscopy: Both the size and site of the perforation determine the surgical approach

- **Size of perforation:** Is the perforation limited or subtotal? Microperforations may have a higher failure rate than larger perforations
- **Site of perforation:** Does the perforation extend far into the anterosuperior

quadrant? Does it only involve the posterior quadrant?

- **What is the status of the middle ear mucosa?** Is it normal or granular/ polypoidal? Is there airflow through the perforation with a Valsalva manoeuvre?
- **Is the handle of the malleus medialised?** This may necessitate an ossiculoplasty even in the presence of an intact ossicular chain
- **Is an ossiculoplasty required?**
- **Does the ossiculoplasty need to be staged?**
- **What is the status of the contralateral ear?**

Audiometry: This should have been done recently *i.e.* within the preceding 3months. Correlate the size of the perforation with the audiogram, particularly the air-bone gap. *Lerut, Pfammater & Linder* investigated the correlation between air-bone gap and perforation size. There was a strong correlation between air-bone gap and increasing perforation size; however, the location (anterior/posterior) had no impact on hearing. The greatest changes in air-bone gap were at 0.5 and 4kHz, and the smallest changes at 2kHz. The audiograms thus revealed a consistent “V”-shaped pattern with the turning point at 2kHz. This can be explained by the fact that 2kHz is the resonance frequency of the middle ear; thus, hearing is better preserved at this frequency. The clinical significance is that one can predict the expected air-bone gap by looking at the size of the perforation. If the audiogram does not correspond with the expected findings, then additional middle ear pathology must be expected. ***If the air-bone gap is greater than 30dB, then an ossiculoplasty may be required.***

Tympanometry: Tympanometry provides additional information about the patient's middle ear function; it can also be used to assess eustachian tube dysfunction (see below). The curve is always flat in the presence of a tympanic membrane perforation, but the volume measurements are of interest.

Eustachian tube function: Successful myringoplasty depends on ventilation of the middle ear and mastoid which in turn affects the final position of the reconstructed tympanic membrane.

- **CT scan:** The best assessment of eustachian tube function is a CT scan of the mastoid; favourable findings are a well-aerated middle ear and a well-pneumatised mastoid
- **Tympanometric volume:** This is a good indicator of eustachian tube function and ventilation of the middle ear in the presence of a tympanic membrane perforation when CT scanning is not available. As a general rule, values for ear canal volume in the presence of an intact tympanic membrane should be approximately 1,5 - 2.0ml (adults). With a perforation of the tympanic membrane, the ear canal volume measurement should be high, because the instrument will measure the volume of the entire middle ear space and mastoid in addition to the volume of the ear canal (4-5mls in adults). If the volume is less than this (e.g. 2,5-3ml) then ventilation of the middle ear cleft and mastoid must be poor
- **Valsalva manoeuvre:** Absence of a positive Valsalva test *i.e.* absence of air-flow through the perforation on performing a Valsalva manoeuvre, identifies patients at risk of poorer outcome

Surgical Approaches

Optimal graft take depends on securing the graft; this in turn depends on having sufficient surgical exposure to stabilise the graft. **Three different approaches** may be used *i.e.* **transcanal, endaural or retroauricular.**

Transcanal approach: The operation is performed through an ear speculum placed in the external ear canal. Because exposure is one of the limiting factors of the transcanal approach, its use is limited to repairing traumatic perforations or in cases where there is a wide ear canal with a posterior perforation. The ear canal must be wide enough, and one should be able to visualise the entire margins of the perforation; most often this would apply to posterior perforations. The anterior margin of an anterior perforation may be obscured by an overhanging canal wall.

Endaural and retroauricular approaches: These afford better exposure. These two approaches will next be discussed in more detail.

Endaural Approach

The endaural approach entails making an incision between the tragus and helix; the entrance to the ear canal is then stretched open with endaural retractors. It is a good approach to use for posterior perforations. While the view is better than with a transcanal approach, it is **not suited to anterior perforations.**

Surgical Steps

- Infiltrate the site of the endaural skin incision as well as the ear canal in 4 quadrants with local anaesthetic (lido-caine 1% and adrenaline diluted to 1:200 000), using a nasal speculum to expose the ear canal

- Make a skin incision in the bony external canal with a #15 blade from the 12 o'clock position, spiralling upwards between the cartilages of the helix of the pinna and tragus (*Figure 1*). The incision is 1,5cm in length and extends down to the bone

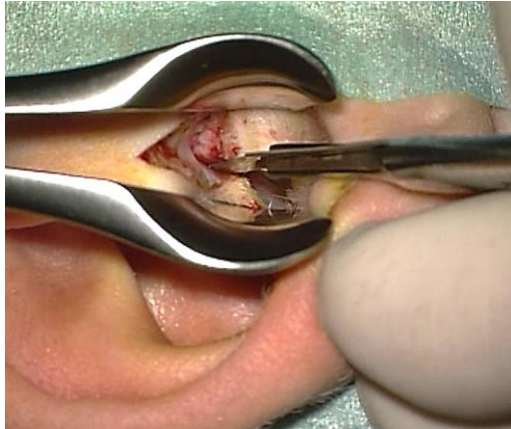


Figure 1: Endaural incision at 12 o'clock in right ear canal

- Achieve haemostasis with bipolar cautery
- Using a #11 blade, make a skin incision in the posterior aspect of the bony external canal parallel to the annulus, starting at 8 o'clock (for right ear) and ascending in a spiral fashion to meet the endaural incision at 12 o'clock (*Figure 2*)
- Use a Key raspatory to reflect the canal skin and soft tissue laterally and away from the edges of the tympanomeatal flap (*Figure 3*)
- Make an incision anteriorly in the bony canal skin, parallel to the annulus and remaining medial to the cartilage of the ear canal. The incision starts at 2 o'clock and meets the endaural skin incision at 12 o'clock (*Figure 4*)
- Place 2 endaural retractors in the ear canal to improve exposure (*Figure 5*)

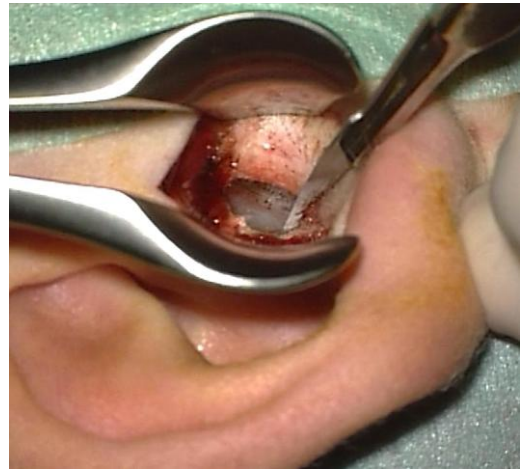


Figure 2: Posterior canal incision that meets endaural incision

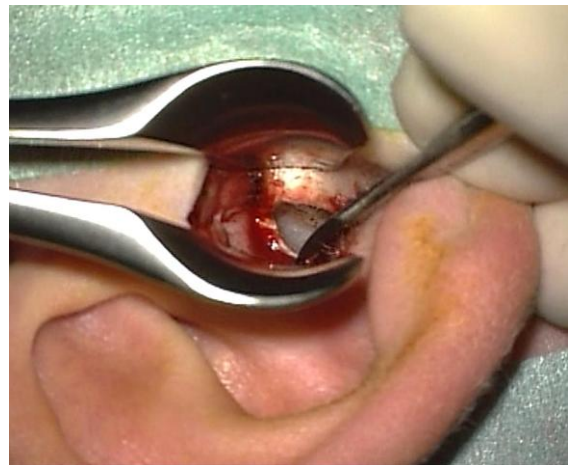

Figure 3: Reflecting canal skin and soft tissue laterally

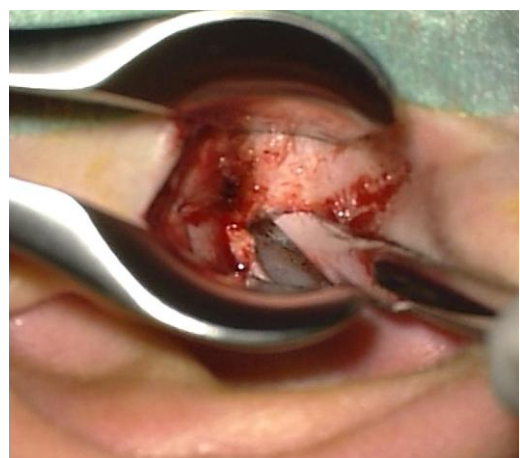


Figure 4: Anterior incision starting at 2 o'clock

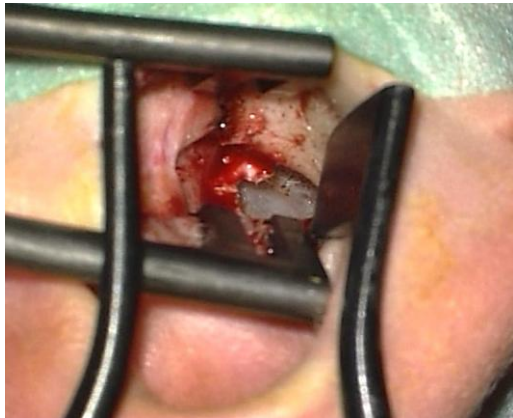

Figure 5: Placement of retractors

- Freshen the edges of the perforation using a sickle knife before elevating the tympanomeatal flap
- Elevate a tympanomeatal flap using a Fisch microraspatory and adrenaline gauze
- If a prominent tympanosquamous suture prevents good exposure, it must be drilled away using a 2,7mm diamond drill (Figure 6). Avoid bone dust from entering the ear, by placing gelfoam soaked in Ringer's lactate into the perforation. Never leave gauze or cotton in the surgical field that can be caught up in the drill bit.
- The middle ear is entered by elevating the tympanomeatal flap at the level of the posterior tympanic spine (Figure 7)

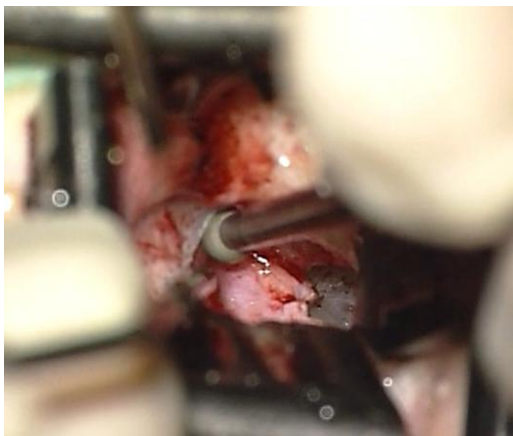


Figure 6: Tympanosquamous suture drilled away

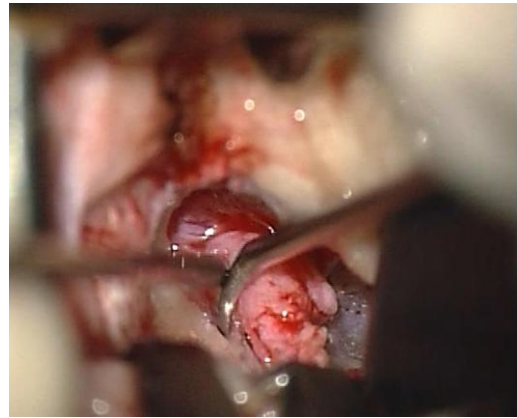

Figure 7: Elevating the tympanomeatal flap

- The annulus starts at this level and can be easily dissected free of its sulcus using a microraspatory as a shovel
- Identify and preserve the *chorda tympani* immediately beneath the tympanic spine at this level
- To assess ossicular chain mobility, use the small end of a curette to remove the posterior tympanic spine and bone of the posterior canal wall until the incus, incudostapedial joint, lateral process of the malleus and round window are visible (Figure 8)

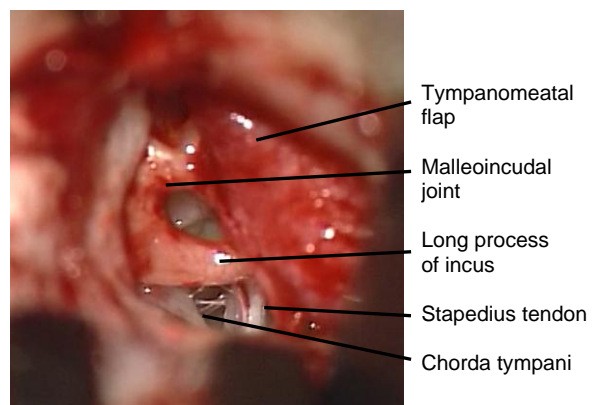


Figure 8: Middle ear structures after curetting posterior tympanic spine

- Use a 1,5mm, 45° hook to palpate the malleus and incus. If the ossicular chain is intact, then proceed to graft the perforation

- Tragal perichondrium is generally harvested via the endaural incision and is placed as an underlay graft beneath the edges of the perforation. Posteriorly and superiorly, it is laid onto the bony canal lateral to the posterior tympanic sulcus. Temporalis fascia may also be used as a graft; it is harvested via the endaural incision or through a separate postauricular incision
- Return the tympanomeatal flap to its original position and place gelfoam pledgets over the graft to secure it over the posterior tympanic sulcus
- Close the endaural skin incision with 3/0 Nylon sutures

Retroauricular Approach

A retroauricular incision is made close to the hairline with soft tissue and pinna reflected anteriorly. It is favoured for anterior perforations. It allows one to do a circumferential canalplasty where there is a significant anterior bony overhang.

Surgical Steps

- Infiltrate the postauricular sulcus with lidocaine 1% and adrenaline diluted to 1:200 000. Then advance the needle and infiltrate the tissues antero-inferiorly and antero-superiorly
- Use a Lempert's speculum to visualise the bony-cartilaginous junction of the ear canal, and inject the 4 quadrants of the skin of the ear canal (*Figure 9*)
Make a postauricular incision about 2cm behind the retroauricular sulcus extending from the upper border of the pinna to the level of the mastoid tip. Make light crosshatchings with a scalpel before incising the skin to facilitate aligning the skin when closing the wound

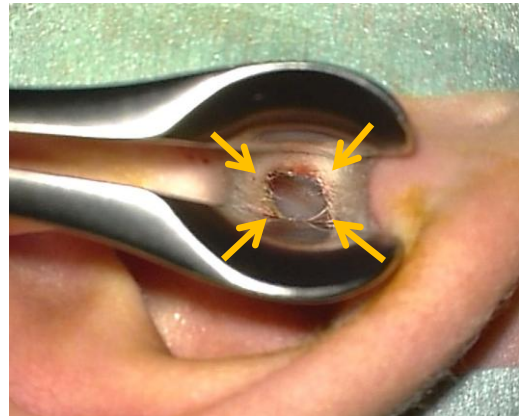


Figure 9: Points of injecting ear canal

- Use a large rake retractor to reflect the pinna anteriorly with the left hand while developing a tissue plane anteriorly toward the external ear canal, using a scalpel with a #10 blade
- The scrub nurse or assistant uses a large suction tube to clear excess blood so that no time is lost trying to achieve haemostasis while elevating the skin
- As the flap is developed the posterior auricular muscle is encountered. This is transected to get into the correct surgical plane
- Superiorly, the temporalis fascia comes into view (*Figure 10*)

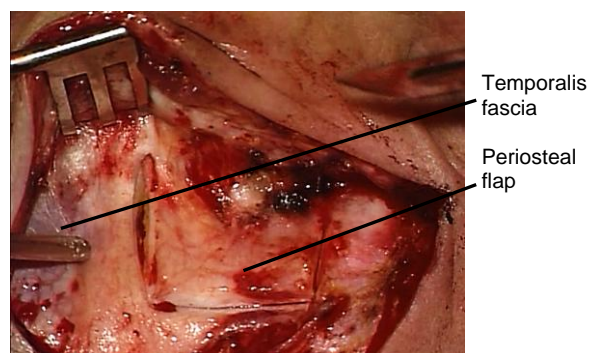


Figure 10: Temporalis fascia and retroauricular periosteal flap

- A retroauricular anteriorly based periosteal flap is now developed. The vertical incision is made approximately 1,5cm from the ear canal (*Figure 10*). Using a #10 blade, extend the superior incision anteriorly along the *linea tem-*

poralis up to 12 o'clock relative to the bony ear canal. Extend the inferior incision to the inferior border of the ear canal. Elevate the periosteal flap from the bone with a mastoid raspatory up to the 12 o'clock position until both the *Spine of Henlé* and the bony external canal are exposed

The next step is to raise a meatal skin flap. The authors favour a **spiral flap technique**, which should be practiced in the temporal bone laboratory and will next be described (Figure 11). ([Spiral flap video](#))

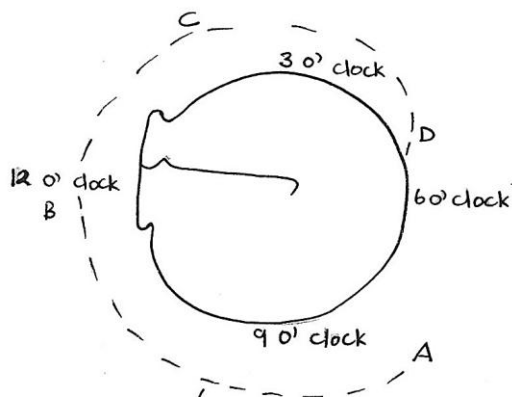


Figure 11: Incisions for spiral flap technique

- Elevate the periosteal flap up to about 2mm medial to the lateral edge of the bony external ear canal
- Using a #11 blade, enter the ear canal via a transverse incision in the posterior ear canal skin at about 8 o'clock (right ear)
- The ear canal is then visible through the incision (Figure 12)
- Cut with the scalpel in a *cephalad* direction and extend the incision superiorly up to 12 o'clock. It is important that the blade remains on bone
- The first incision now extends from A - B (Figures 11, 13)

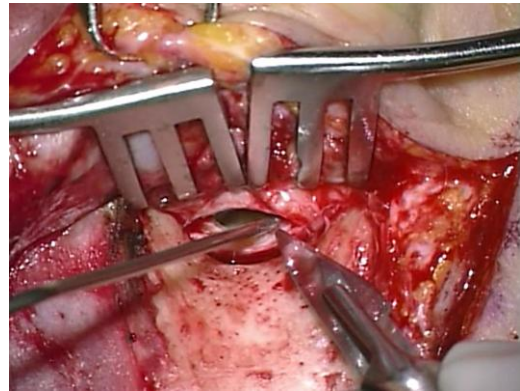


Figure 12: Incising posterior ear canal

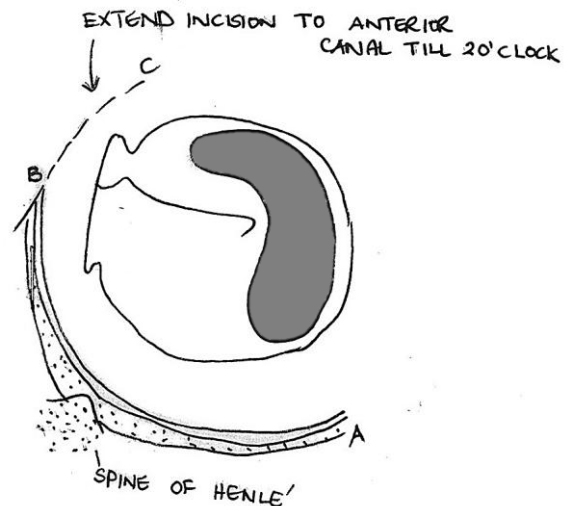


Figure 13: Posterior incision extended as spiral incision to anterior canal wall

- Make an incision from C - B in the skin of the anterior wall of the ear canal starting at 2 o'clock and extended superiorly to meet the previous incision at 12 o'clock (Figure 13, 14). This incision runs lateral to the tympano-squamous suture line and also must remain on bone and medial to tragal cartilage; if the incision is placed too laterally then the tragal cartilage will be injured

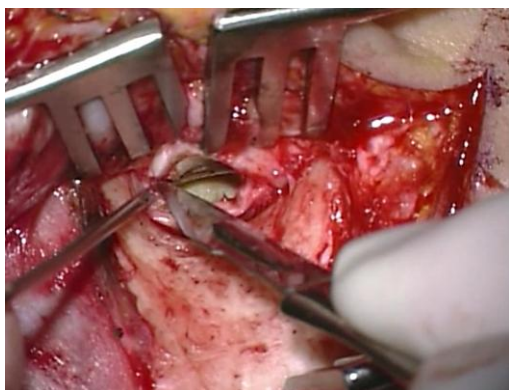


Figure 14: Incising anterior ear canal

- Use a Key raspatory to elevate the lateral canal skin from the underlying bone (Figures 15, 16)

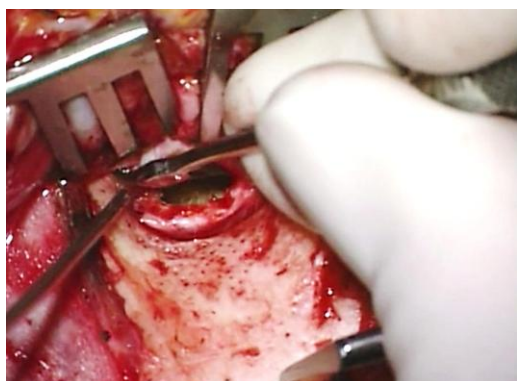


Figure 15: Elevating skin from bone

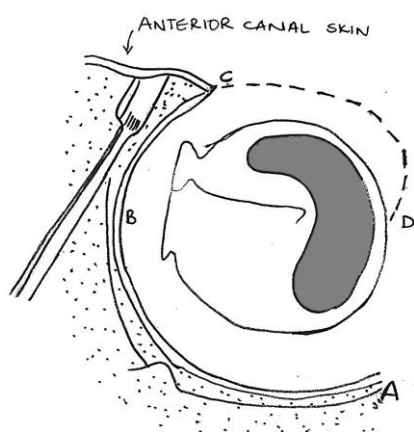


Figure 16: Completing incision in anterior canal wall

- Attach a sharp towel clip to the periosteal flap at the level of the canal to reflect the pinna and soft tissue forward

- Two self-retaining retractors are placed superiorly and inferiorly to reflect the soft tissue and to improve exposure. In children, one retractor is sufficient
- Next incise the meatal skin anteroinferiorly from D to C, starting close to the tympanic membrane at about 5 o'clock (Figure 16). The incision spirals laterally and superiorly along the anterior canal wall to meet the earlier incision made in the anterior canal at 2 o'clock (right ear)
- A common mistake when creating this flap for the first time is not incising the skin fully onto bone; this causes the flap to tear when elevating it with the microraspatory. It is therefore important that the blade stays hard on bone when making the canal incisions
- Elevate the meatal skin flap circumferentially from the underlying bone with a Fisch microraspatory (Figure 17)




Figure 17: Fisch microraspatory used to elevate meatal skin off bone

- Never apply suction directly to a meatal skin flap to avoid injuring the skin flap
- To keep this dissection blood-free place adrenaline-soaked gauze between the Fisch microraspatory and the meatal skin, and suction excess blood through the adrenaline-soaked gauze
- Keep the blade of the Fisch microraspatory vertical to the bone and use the shoulder of the instrument to push against the adrenaline gauze to atraumatically elevate the very fragile meatal skin (Figures 17, 18)

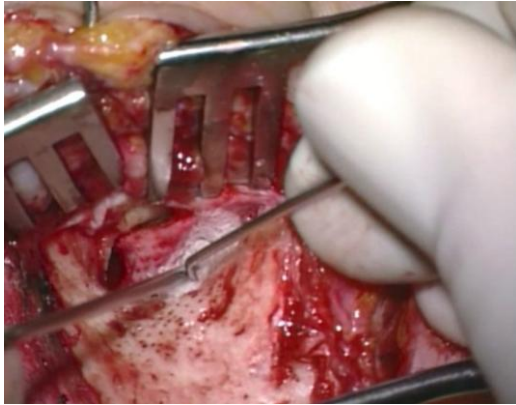


Figure 18: Elevating meatal skin

- Elevate the meatal skin until the posterosuperior edge of the tympanic membrane and the anteroinferior overhang of bone are exposed
- The skin flap is tightly bound to the underlying bone at the tympanosquamous suture line (located posterosuperiorly) and may be dissected free using the following technique:
 - Using a raspatory like a shovel, free the skin flap posterior to the suture
 - Then elevate the flap anterior to the suture
 - There may still be a remaining bridge of soft tissue connection to the suture line which is then cut with Bellucci scissors
- Using a #11 blade incise the posterior limb of the meatal skin flap 2mm lateral and parallel to the annulus (Figures 19, 20)
- Use Bellucci scissors to continue incising the meatal skin flap 2mm lateral to and parallel to the annulus until the anterior part of the flap is reached (Figures 20, 21)
- Transect the remaining meatal skin to 6 o'clock, 2mm lateral to the annulus, using an Iowa raspatory or a round knife (Figure 21)

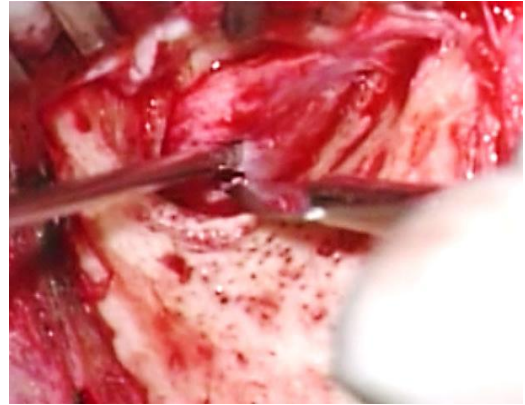


Figure 19: Incising posterior limb of meatal skin flap 2mm lateral to annulus

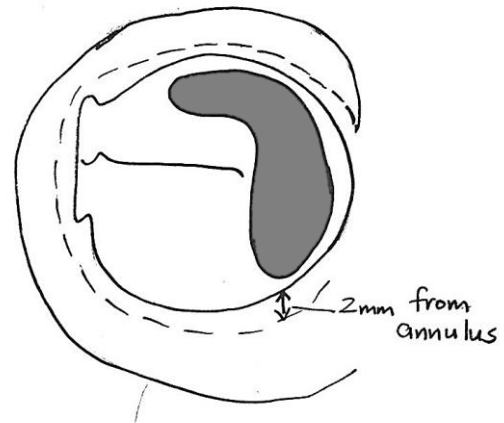


Figure 20: Incise posterior limb of meatal skin flap 2mm lateral to and parallel to the annulus

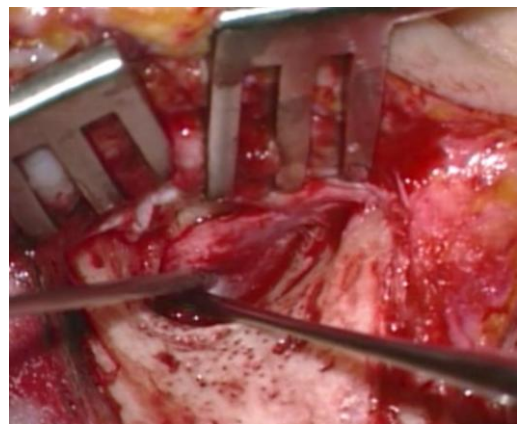


Figure 21: Extending incision anteriorly, remaining 2mm lateral to and parallel to annulus

- Using a larger (Iowa) raspator, dissect the meatal skin free from the bony canal lateral to this circumferential incision. Using a bigger instrument avoids injuring the inferiorly based pedicle (Figure 22)

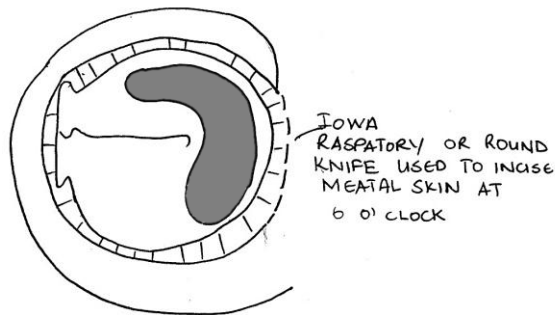


Figure 22: Transect remaining meatal skin to 6 o'clock, 2mm lateral to the annulus

- Elevate the lateral aspect of the anterior meatal skin flap with a Key raspator and using two hands, advance the raspator over the lateral rim of the tympanic bone (Figure 23)

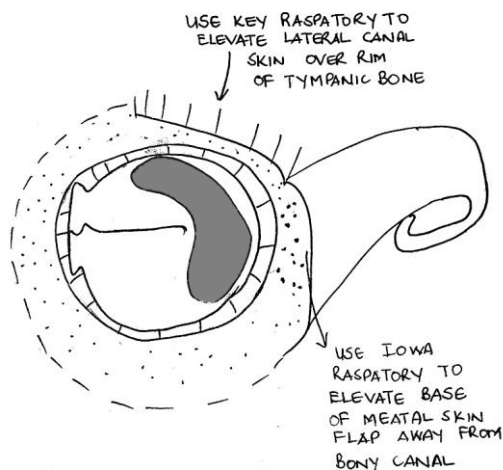


Figure 23: Flap pedicled inferiorly and elevated from canal wall

- Once the lateral edge of the tympanic bone is reached, keep the tip of the instrument in contact with the bone and

underlying tissue but swing the handle of the Key raspator anteriorly so that the soft tissue is elevated out of the bony external canal, leaving it pedicled inferiorly (Figures 23, 24)

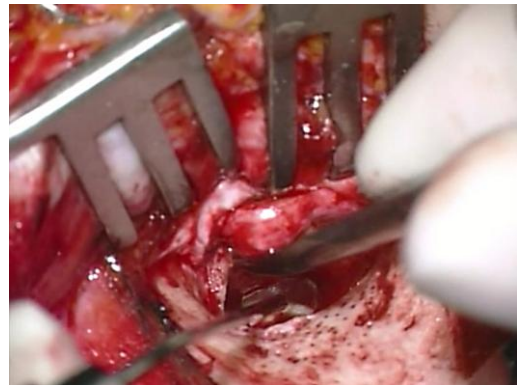


Figure 24: Soft tissue is elevated out of the bony external canal

- Keep the spiral of elevated meatal skin out of the surgical field with the aluminium strip or ribbon of the surgeon's mask which has been sterilised. First, pass the ribbon through the teeth of the self-retaining retractor (Figure 25). Then use artery forceps to place it against or pass it around the meatal skin flap (Figure 26). Next fold the ribbon back over the top of the retractor (Figure 27)

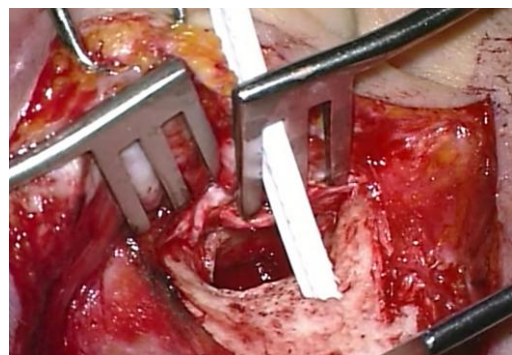

Figure 25: Ribbon passed through teeth of self-retaining retractor

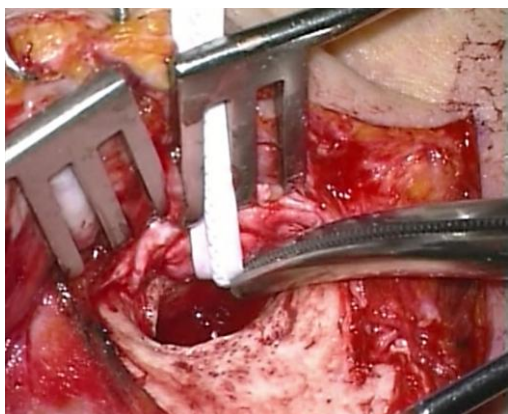


Figure 26: Ribbon passed around meatal spiral flap

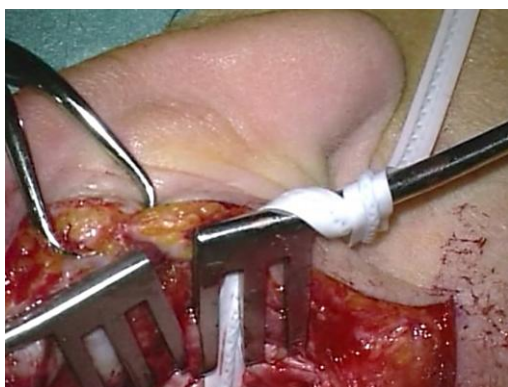

Figure 27: Ribbon secured to self-retaining retractor

Canalplasty ([Canalplasty video](#))

It is imperative to have an adequate view of the annulus as well as all the edges of the perforation to do an adequate myringoplasty or tympanoplasty operation. With perforations only involving the posterior quadrant where the entire margin of the perforation is visible, performing a canalplasty is unnecessary. However, there is often a bony overhang anteriorly and/or posteriorly which restricts a surgeon's view. If the perforation involves the anterior quadrant then it is necessary to do a canalplasty.

Surgical steps

- Standard retroauricular approach
- Elevate meatal spiral flap

- If there is a tympanic membrane perforation, place gelfoam soaked in Ringer's lactate over the perforation to avoid bone dust entering the middle ear
- Starting with a 2,7mm rough diamond burr, enlarge the ear canal by drilling away any bony overhangs
- Start by drilling posteriorly, then move inferiorly and finally drill the anterior canal wall
- The technique of skeletonisation is important. With correct technique the bluish colour of the temporomandibular joint (TMJ) will show through the irrigation; this should alert one to stop drilling before the joint is entered
- It is important to check that burr sizes are correct by first placing a new burr in the canal before using it
- Always **drill under direct vision** and never behind overhanging edges of bone. In this way one avoids opening mastoid air cells or injuring the facial nerve posteriorly and TMJ anteriorly
- Use the Fisch microraspatory (with adrenaline gauze) to elevate the meatal skin before drilling the bony overhangs (Figure 28)

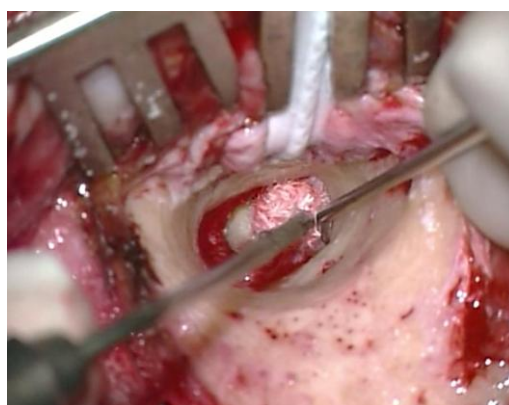

Figure 28: Microraspatory used to elevate meatal skin using adrenaline-soaked gauze

- When drilling close to meatal skin, a diamond burr is used so that the meatal skin is not injured by the burr

- Hold the microraspatory perpendicular to the bone at the level of the annulus; the tip of the microraspatory is not visible because of the anterior bony overhang. Using this technique, one can determine how much bone needs to be removed before reaching the annulus (*Figure 29*)

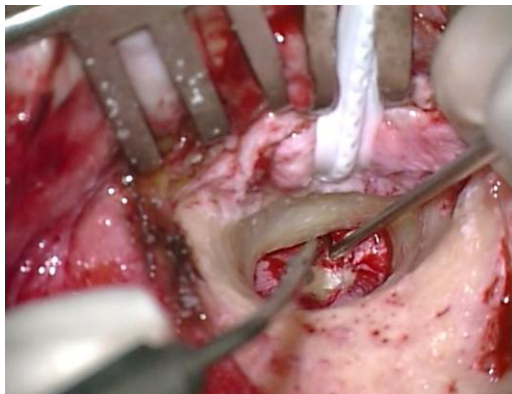


Figure 29: Tip of microraspatory used to determine how much bone needs to be removed lateral to annulus

- This bony overhang is then drilled away, using a small diamond burr (*Figure 30*)

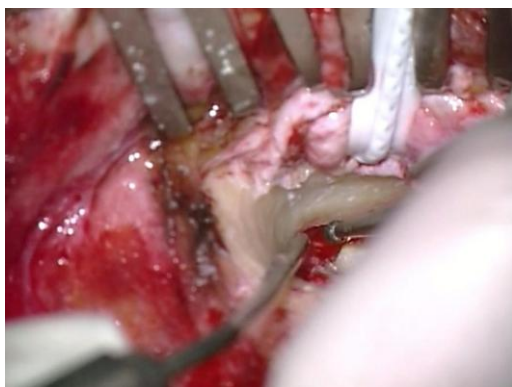

Figure 30: Bony overhang drilled using a small diamond burr

- The ***inferior trough technique*** allows a surgeon to gauge the depth of the annulus: using a diamond burr, drill at 6 o'clock from medially-to-laterally to create a groove. Continue to drill until the white colour of the annulus be-

comes visible at the level of the sulcus (*Figure 31*)

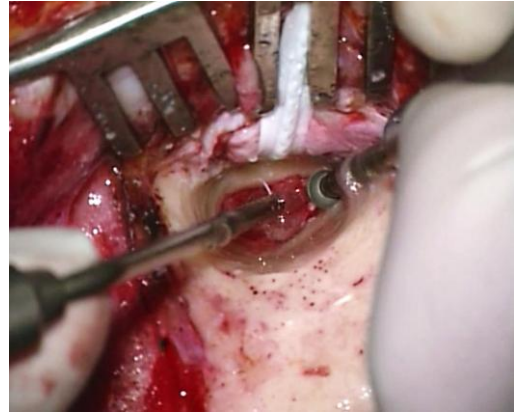


Figure 31: Inferior trough technique

- Now continue to expand the drilling from the groove outwards and circumferentially
- Once the canalplasty has been completed the ***entire annulus should be visible with one view of the microscope*** and no bony overhangs should remain (*Figure 32*)

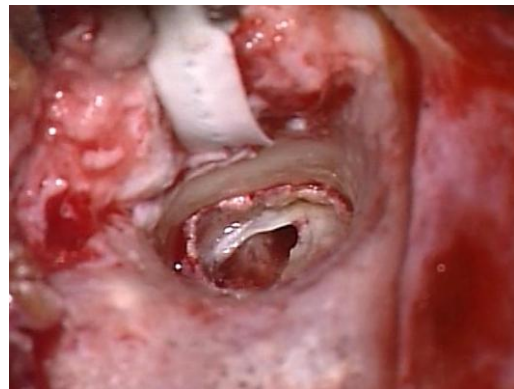


Figure 32: Completed canalplasty with entire annulus visible and no bony overhang

- Following grafting of the tympanic membrane perforation (see later) the meatal skin flap is replaced (*Figure 33*)

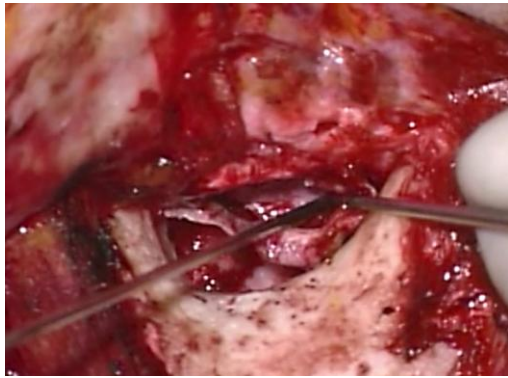


Figure 33: Meatal skin flap being replaced

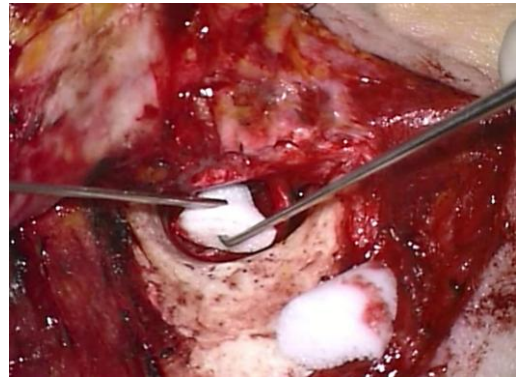


Figure 35: Ivalon® used to secure the meatal skin

- The meatal skin is secured with gel-foam pledgets placed medially over the graft. Two pieces are cut from an Ivalon® ear wick and inserted laterally into the ear canal over the meatal flap (Figures 34, 35). Ivalon® has a smooth surface which is placed on the outside (facing the meatal skin) to allow for atraumatic removal 1 week postoperatively
- The postauricular periosteal flap is replaced and secured with 3/0 Vicryl sutures (Figure 36)
- Ensure that the skin of the meatal flap is applied to the bony canal and extends lateral to the Ivalon® ear wick (Figure 37)

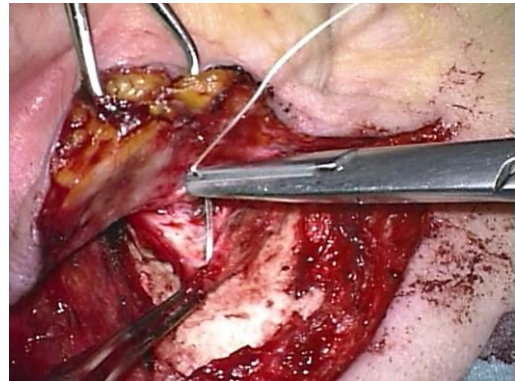


Figure 36: Securing the retroauricular periosteal flap

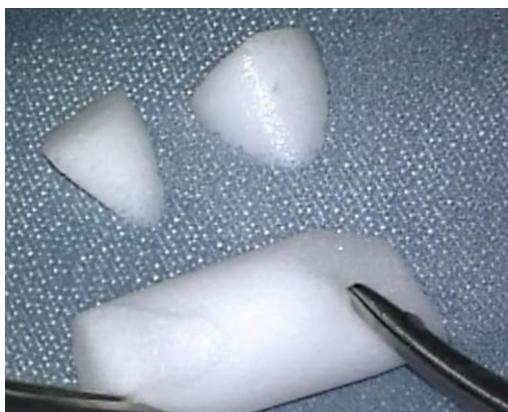

Figure 34: Ivalon® ear wick

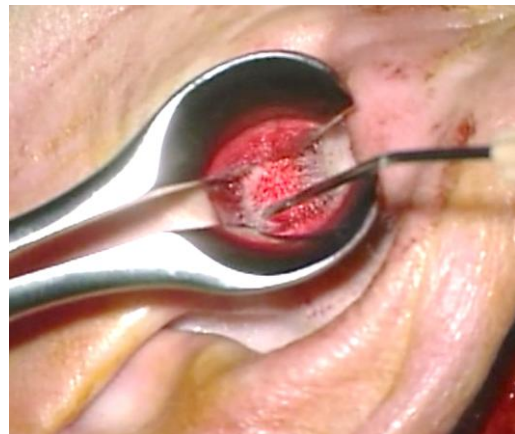


Figure 37: Checking correct placement of meatal skin

Antrotomy

An antrotomy is performed in conjunction with a myringo- or tympanoplasty when eustachian tube function is questionable or in the presence of polypoidal middle ear mucosa obstructing the epitympanum (*Figure 38*).

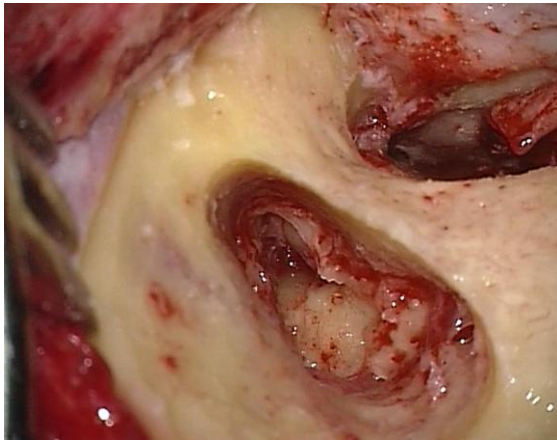


Figure 38: Antrotomy defect

The detailed surgical steps for antrotomy are presented in the chapter on [Mastoidectomy and epitympanectomy](#)

Epitympanic patency is determined with the *water test*: Ringer's solution is irrigated into the antrum to test whether there is free communication between the antrum and the middle ear (*Figure 39*)

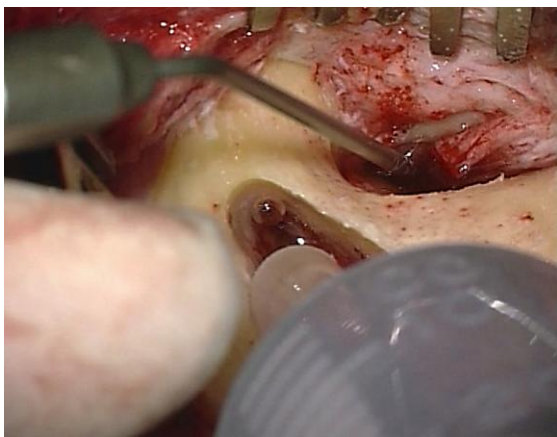


Figure 39: Antrum irrigated with Ringer's solution

- If the test is *positive*, there is no need to further explore the epitympanum
- If the test is *negative*, then one needs to explore the epitympanum
- If abnormal mucosa is removed from the epitympanum but the ossicles are left intact, this is defined as an *epitympanotomy*
- If malleus head and incus need to be removed to re-establish patency, this is referred to as an *epitympanectomy*
- Following the procedure, a groove is drilled posteriorly into the mastoid bone to accommodate a transmastoid drain
- A separate stab incision is made posterior to the retroauricular skin incision and the drain is fixed to the skin using a silk suture
- The patient may perform Valsalva manoeuvres from the 2nd day following surgery
- The mastoid drain is usually removed after 2-4 days

Grafting tympanic membrane perforations

Choice of graft material

- *Temporalis fascia* is widely used to reconstruct the tympanic membrane. It is easily accessible, and long-term results are comparable to that of cartilage tympanoplasty. An advantage of temporalis fascia is that recurrent or residual cholesteatoma can easily be identified behind the reconstructed tympanic membrane
- *Tragal perichondrium*
- *Cartilage* is preferred in certain instances due to its resilience: it may be used to reinforce an atrophic tympanic membrane; it is used in addition to fascia in a closed mastoidoepitympanectomy to reconstruct the posterior canal wall; and certain middle ear prostheses

require reinforcement of the overlying tympanic membrane to prevent extrusion through tympanic membrane

Harvesting temporalis fascia

Temporalis fascia has a superficial and a deep layer. The deep layer is used for grafting because it is thicker and more resilient. The fascia is easily harvested from the retro-auricular region if a retro-auricular approach has been used via the same incision. It is preferable to harvest the fascia at the end of the procedure once the surgeon knows how much fascia is required.

- An assistant exposes the fascia by superiorly retracting skin and soft tissue with a rake retractor (*Figure 40*)
- Divide and separate the superficial layer of fascia from the deep layer with tympanoplasty scissors
- Make a transverse incision in the deep layer of fascia parallel to *linea temporalis* with a #11 blade
- Undermine the undersurface of the fascia via this incision and separate it from the temporalis muscle with scissors (*Figure 41*)
- Harvest the appropriate amount of fascia with scissors taking only as much as is needed so that should the patient require revision surgery, additional fascia can be harvested
- Compress the fascial graft between two gauze swabs, but do not dry the fascia
- Then place the graft on a silicone block
- The scrub nurse holds one corner of the graft, while the surgeon holds the other corner with anatomical forceps, and using a #10 blade, scrape the graft clean of muscle fibres (*Figure 42*)
- Trim uneven edges with a #10 blade
- An incision is made in the flap with a knife to accommodate the *tensor tympani* tendon at the anticipated location of the malleus handle (*Figure 43*)

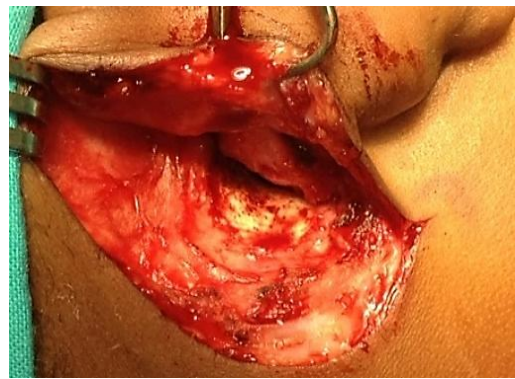


Figure 40: Exposing temporalis fascia

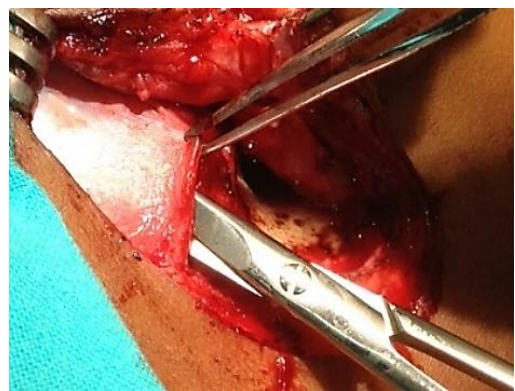


Figure 41: Undermining deeper layer of temporalis fascia

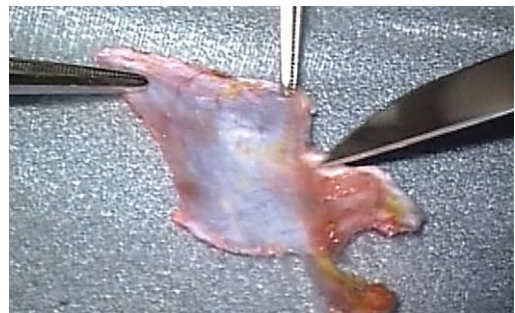

Figure 42: Scraping muscle off fascia

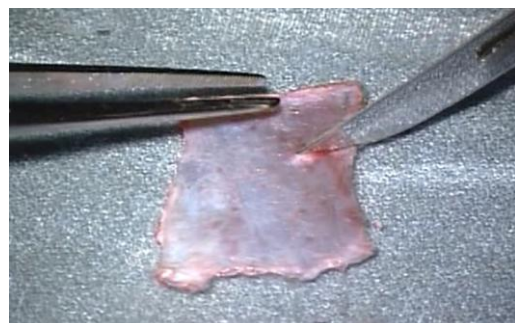


Figure 43: Incision to accommodate tensor tympani tendon

- When doing revision surgery, it is possible to extend the postauricular incision superiorly to find additional temporalis fascia (*Figure 44*)

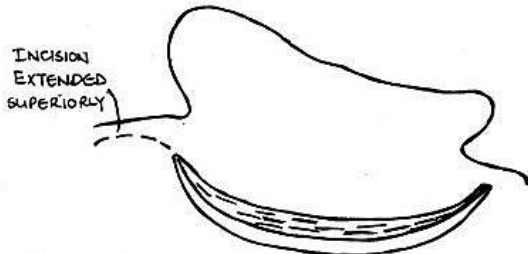


Figure 44: Extended postauricular incision for additional temporalis fascia

Harvesting tragal cartilage and tragal perichondrium

Tragal cartilage is easily harvested by exposing the upper end of the tragal cartilage through an endaural approach

- Hold the tragal cartilage with surgical forceps while dissecting the soft tissue off the cartilage with tympanoplasty scissors
- After exposing the amount of cartilage required for reconstruction, resect cartilage with overlying perichondrium with tympanoplasty scissors
- Using the operating microscope strip the tragal perichondrium from the cartilage with a microraspator. The perichondrium may also be left attached to the tragal cartilage when reconstructing the posterosuperior canal wall
- To thin cartilage, hold it with Hudson Brown forceps and section the cartilage with a new #10 blade

Grafting Techniques

The authors use the terms “*underlay*” and “*overlay*” to refer to the position of the graft relative to the bony (annular) sulcus. (In other texts it may refer to the position of the graft in relation to the tympanic membrane)

- With *underlay technique* the graft is placed medial to the remnant of the tympanic membrane and anterior tympanic sulcus
- With *overlay technique* the graft is placed lateral to the tympanic sulcus

Underlay technique is most often used for perforations involving the anterior quadrant. The graft is always placed medial to the malleus handle. Larger perforations often require a combination of anterior underlay *and* posterior/inferior overlay grafting techniques.

Grafting limited perforations of the posterior quadrant (Figure 45)

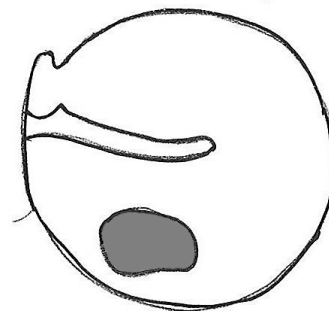


Figure 45

These surgical steps are discussed in detail under *endaural approach*.

Grafting perforations that reach the anterior quadrant (Figure 46)

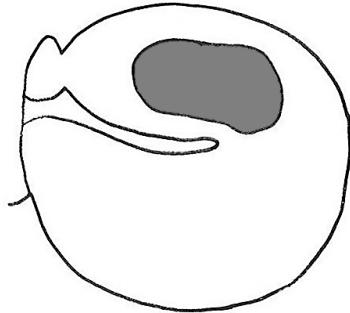


Figure 46

- Retroauricular approach is used
- Canalplasty is done
- The **annulus is not elevated between 2 and 4 o'clock** (right side) as this will cause blunting of the anterior tympanomeatal angle and lateralisation of the tympanic membrane resulting in reduction of vibratory properties of the tympanic membrane
- If the perforation involves the antero-inferior quadrant then the tympanomeatal flap is divided posteriorly after it has been elevated (Figure 47)

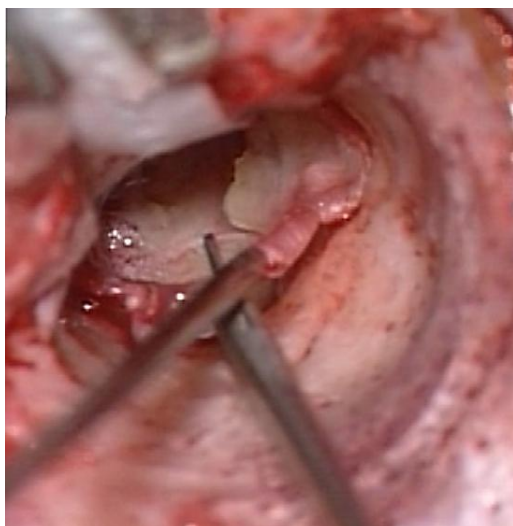


Figure 47: Dividing the tympanomeatal flap posteriorly

- Scrape the undersurface of the tympanic membrane remnant with a 1,5mm, 45° hook
- Anteriorly, underlay the graft under the edge of the tympanic remnant
- If the perforation extends inferiorly or posteriorly then underlay the graft anteriorly but overlay it posteriorly in the inferior or posterior quadrants
- Replace the meatal skin flap (Figure 48)
- Secure the fascia and meatal skin flap with gelfoam

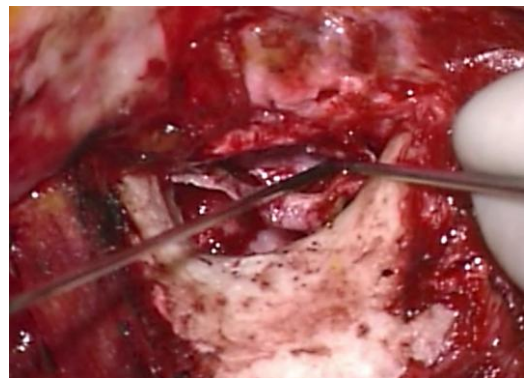

Figure 48: Meatal skin flap is being replaced

Grafting perforations that reach the anterosuperior quadrant (Figure 49)

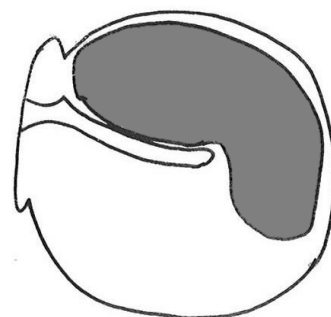


Figure 49

- Use a retroauricular approach
- Complete a canalplasty
- Elevate and divide the tympanomeatal flap posteriorly (Figure 47)

- Scrape the undersurface of the tympanic membrane remnant with a 1,5mm, 45° hook
- ***Fixing the graft anteriorly requires special anterior support***
- Detach the tympanic annulus between 1 and 2 o'clock (right ear) using a microraspatory to create a "buttonhole" anteriorly between annular ligament and bone (*Figure 50*)
- The fascial graft is placed medial to the malleus
- A small "tongue" of the graft is manoeuvred with a 1,5mm 45° hook, as close as possible to the "buttonhole"
- Use a microsuction tube to suck onto and to pull the "tongue" of temporalis fascia through the "buttonhole" and then use a 1,5mm hook to advance the graft into position (*Figure 51*)

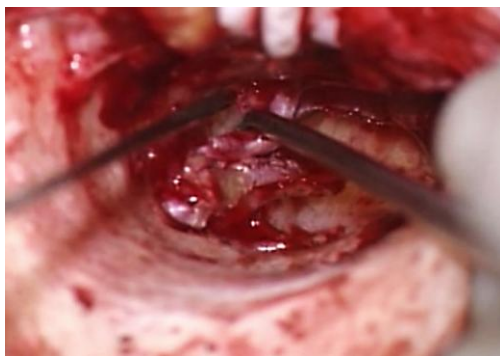

Figure 50: Detach tympanic annulus between 1 and 2 o'clock to create "buttonhole" anteriorly

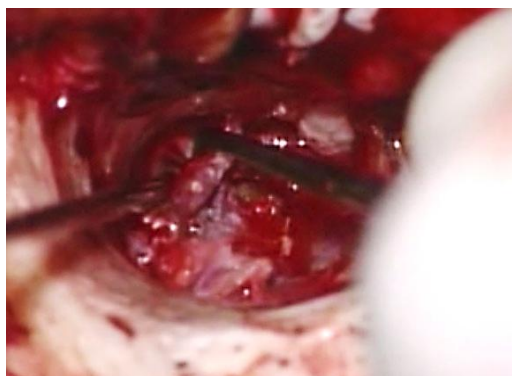


Figure 51: Use a microsuction tube to suck and pull "tongue" of temporalis fascia through "buttonhole"

Grafting subtotal perforations (Figure 52)

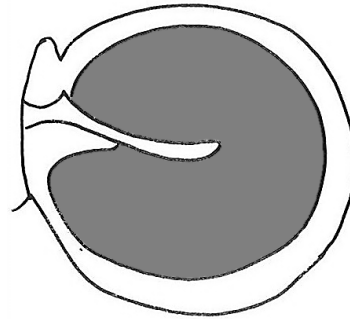


Figure 52

- Use a retroauricular approach
- Complete a canalplasty
- Elevate and divide the tympanomeatal flap posteriorly (*Figure 36*)
- Subtotal perforations may only have a limited remnant of the tympanic membrane anteriorly
- Scrape the undersurface of the tympanic membrane remnant and adjacent bone with a 1,5mm, 45° hook
- Underlay the graft both under the tympanic membrane and malleus handle
- The graft is supported anteriorly by placing small pieces of gelfoam soaked in Ringer's lactate beneath the graft (*Figure 53*)

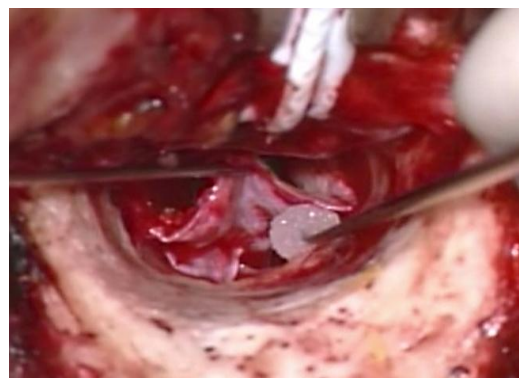

Figure 53: Graft supported anteriorly by gelfoam soaked in Ringer's lactate

- Superiorly both limbs of the fascia overlap just above the neck of the malleus (*Figure 54*)

- Posteriorly and inferiorly, the graft is positioned as an overlay graft

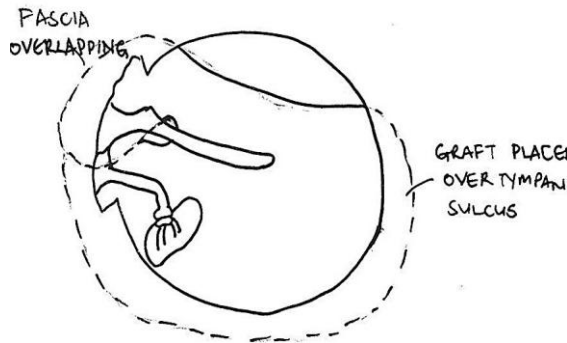


Figure 54: Fascia overlaps just above neck of malleus

- Place gelfoam laterally over the graft to secure it in place over the tympanic sulcus (Figure 55)

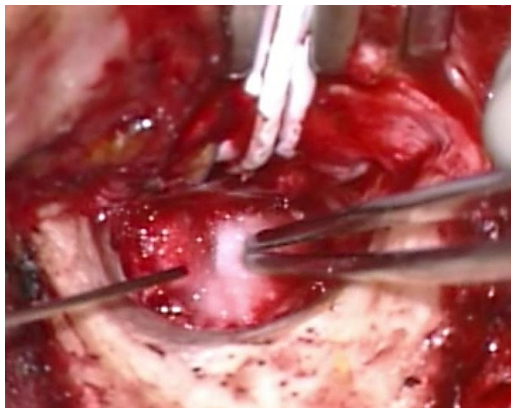

Figure 55: Gelfoam placed laterally to secure graft

Management of severely retracted malleus with chronic otitis media with

Occasionally patients with longstanding chronic otitis media do not develop erosion of the incus, but the malleus handle becomes medialised. In severe cases the umbo of the malleus touches or even attaches to the promontory. This presents a challenge because the tympanic membrane perforation needs to be reconstructed, and the hearing needs to be improved at the same time. If fascia is placed as an underlay graft it will result in Grade 4 atelectasis

and may subsequently re-perforate. **Lateralisation of the malleus** is easily achieved once the incus has been removed. The following is an effective technique to manage a severely retracted malleus:

- The malleus head and anterior malleolar ligament are removed leaving the *tensor tympani* tendon intact
- An incus interposition is then done
- The perforation is grafted with fascia or cartilage by underlay technique
- Because the malleus has been lateralised it facilitates placement of the graft in the proper position

Reconstruction with closed mastoidoepitympanectomy

See the [mastoidoepitympanectomy](#) chapter for a description of reconstruction at the time of primary surgery

- The defect is often located superiorly in the epitympanum
- Use cartilage to reconstruct the defect in the epitympanum
- Place temporalis fascia beneath the handle of the malleus so that the two tongues of the fascia overlap each other in the epitympanum (Figure 56)

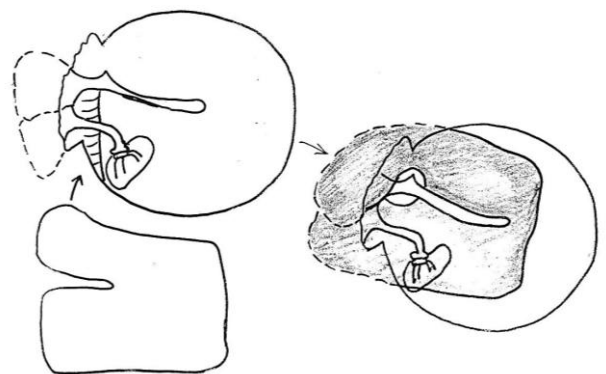


Figure 56: Temporalis fascia placed beneath handle of malleus so that two tongues of fascia overlap

- An alternative technique is to position the graft such that the two tongues are

positioned around the malleus and overlap each other in the middle ear beneath the malleus handle (*Figure 57*)

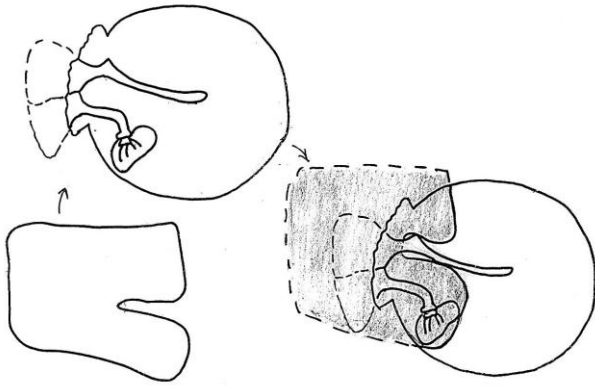


Figure 57: Two tongues overlap in middle ear beneath malleus handle

Reconstruction with open mastoidoepitympanectomy

See the [Mastoidectomy and epitympanectomy](#) chapter for a description of reconstruction at the time of primary surgery

- Drill a circumferential tympanic groove with a small diamond burr to form a new tympanic sulcus
- Place the graft as with repair of a subtotal perforation
- If a 2nd stage ossiculoplasty is planned, then place silastic sheeting in the middle ear and *protympanum*

Ossiculoplasty

Ossiculoplasty is defined as reconstruction of the hearing mechanism by establishing a connection between the tympanic membrane and the oval window. It is covered in detail in the chapter "[Ossiculoplasty](#)"

References

1. Fisch U, May J, Linder T. Tympanoplasty, Mastoidectomy, and Stapes Surgery. New York: Thieme; 2008
2. Lerut B, Pfammatter A, Moons J, Linder T. Functional Correlations of Tym-

panic Membrane Perforation Size. *Otol Neurotol.* 2012; 33:379-86

3. Hol KS, Nguyen DQ, Schlegel Wagner C, Pabst G, Linder TE. Tympanoplasty in chronic otitis media with an intact, but severely retracted malleus: A treatment challenge. *Otol Neurotol.* 2010; 31:1412-6

Acknowledgments

This surgical guide is based on the text by Professor Ugo Fisch (Tympanoplasty, Mastoidectomy, and Stapes Surgery) and the personal experience of Professor Linder, as well as course material for the temporal and advanced temporal bone courses conducted annually by Professors Fisch and Linder at the Department of Anatomy, University of Zurich, Switzerland.

Download meatoplasty video

<https://vula.uct.ac.za/access/content/group/9c29ba04-b1ee-49b9-8c85-9a468b556ce2/Johan%20Fagan%20Surgery%20Atlas/M%20-%20Meatoplasty.avi>

Download spiral flap & canalplasty video

https://vula.uct.ac.za/access/content/group/9c29ba04-b1ee-49b9-8c85-9a468b556ce2/Johan%20Fagan%20Surgery%20Atlas/spiral%20flap%20_%20canalplasty.avi

How to cite this chapter

Harris T, Linder T. (2012). Myringoplasty and tympanoplasty. In *The Open Access Atlas of Otolaryngology, Head & Neck Operative Surgery*. Retrieved from <https://vula.uct.ac.za/access/content/group/ba5fb1bd-be95-48e5-81be-586fbaeba29d/Myringoplasty%20and%20tympanoplasty.pdf>

Authors

Tashneem Harris MBChB, FCORL,
MMED (Otol), *Fisch Instrument
Microsurgical Fellow*

Associate Professor and ENT Specialist
Division of Otolaryngology
University of Cape Town
Cape Town, South Africa
harristasneem@yahoo.com

Thomas Linder MD
Professor, Chairman and Head of
Department of Otorhinolaryngology,
Head, Neck and Facial Plastic Surgery
Lucerne Canton Hospital, Switzerland
thomas.linder@ksl.ch

Editor

Johan Fagan MBChB, FCS(ORL), MMed
Emeritus Professor and Past Chair
Division of Otolaryngology
University of Cape Town
Cape Town, South Africa
johannes.fagan@uct.ac.za

THE OPEN ACCESS ATLAS OF OTOLARYNGOLOGY, HEAD & NECK OPERATIVE SURGERY

www.entdev.uct.ac.za



The Open Access Atlas of Otolaryngology, Head & Neck Operative Surgery by [Johan Fagan \(Editor\) johannes.fagan@uct.ac.za](mailto:johannes.fagan@uct.ac.za) is licensed under a [Creative Commons Attribution - Non-Commercial 3.0 Unported License](https://creativecommons.org/licenses/by-nc/3.0/)

