



Meatoplasty is an operative technique to widen the lateral cartilaginous part of the external auditory canal. Cartilage displaced anteriorly from the *cavum conchae* of the pinna, as well as bulky underlying soft tissue can cause narrowing of the lateral part of the ear canal.¹ The aim of a meatoplasty is to enlarge the lumen of the entrance of the ear canal by removing the obstructing cartilage of *cavum conchae* as well as the underlying soft tissue.

Indications for surgery

There are 2 clinical scenarios where a meatoplasty may be required *i.e.* as an integral part of another otological procedure, or where there is lateral stenosis of the external ear canal

As integral part of other otological procedures

- **Open mastoidoepitympanectomy (MET):** Meatoplasty is an essential routine step at the end of an open MET to provide easy access for cleaning and to assist with ventilation of the mastoid cavity. Failure to do an adequate meatoplasty will result in a lifelong problem of a chronic draining ear. This type of meatoplasty is discussed in the chapter [Mastoidectomy and Epitympanectomy](#)
- **Tympanoplasty, canalplasty, removal of exostosis (bony canal wall intact):** In these procedures it may be mandatory to perform a meatoplasty to improve intraoperative surgical exposure

For lateral stenosis of the external ear canal: Meatoplasty becomes necessary when wax impaction as a result of canal stenosis causes recurrent otitis externa or hearing loss and requires frequent visits to an otolaryngologist.

Canal stenosis may be a result of:

- Congenital stenosis
- Otitis externa
- Iatrogenic following surgery or irradiation
- Trauma

M-Meatoplasty

See video: <http://youtu.be/jvSVteRkUO8>

The authors favour the M-Meatoplasty technique first described by *Mirck* in 1966.²

Anaesthesia

- Antibiotic prophylaxis is not required
- It is performed under local anaesthesia as an outpatient procedure
- The retro-auricular skin behind the conchal cartilage and the underlying soft tissue are infiltrated with 1% lidocaine and 1: 100 000 adrenaline
- The skin and subperichondrial layer of the conchal bowl as well as the posterior ear canal wall are infiltrated with the same solution

Creating the skin flaps

- An assistant retracts the tragus using a microhook to improve exposure (*Figure 1*)

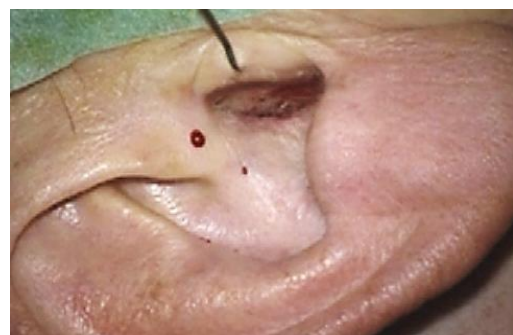

Figure 1: Microhook retracting tragus

- The incisions are mapped out with a marking pen (*Figure 2*)
 - The first line is placed at the anterior border of the *cavum conchae* and at the entrance to the external auditory meatus (*Figure 2*)
 - Two skin markings each measuring 1cm in length and orientated as an inverted “V” are commenced in the centre of the first skin marking (*Figure 2*)

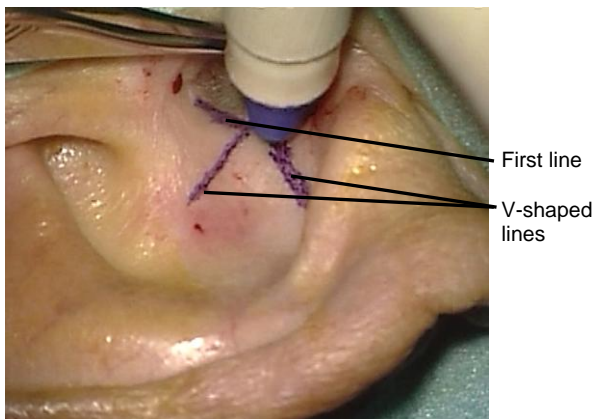


Figure 2: Marking the incisions

- Skin incisions along these lines are made using a #15 blade resulting in three triangular skin flaps (*Figure 3*)

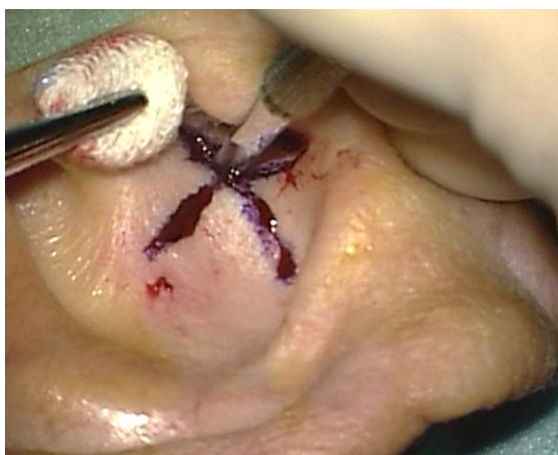

Figure 3: Three skin incisions

- Skin flaps are developed by separating the skin from the underlying *cavum* cartilage using sharp-pointed scissors (*Figure 4*)

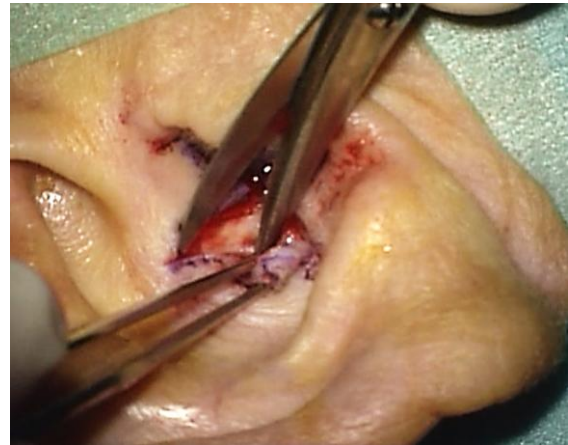


Figure 4: Elevating skin flaps

- Guide sutures are placed at the apices of the 3 triangular skin flaps and mosquito clamps placed at the end of each suture to hold the skin flaps aside (*Figures 5 & 6*)

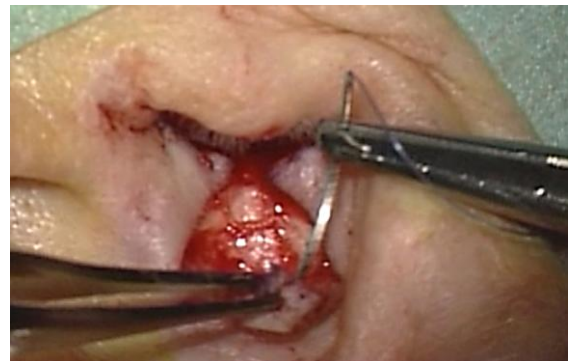


Figure 5: Guide suture being inserted into posterior flap

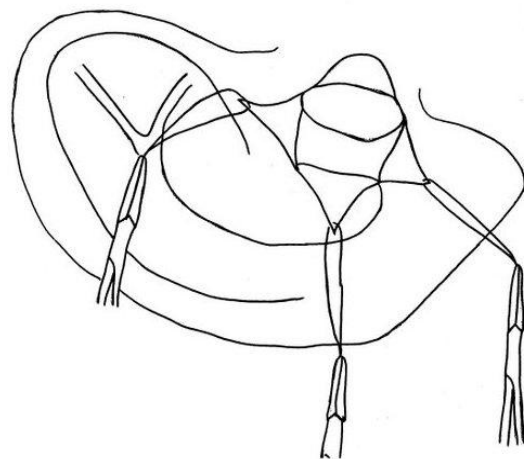


Figure 6: Guide sutures in all 3 flaps

Excision of obstructing cavum cartilage and underlying soft tissue

- A circle of about 1cm diameter is cut out of the *cavum* cartilage (Figure 7)

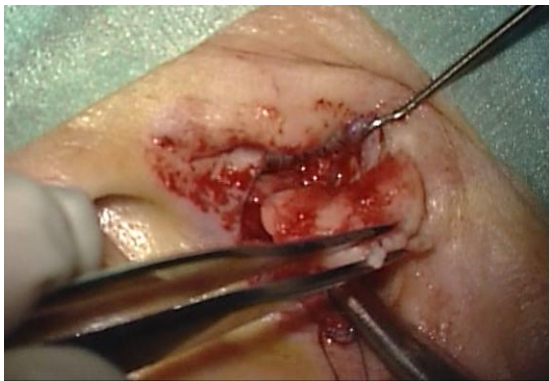


Figure 7: Circle cut out of *cavum* cartilage

- The underlying subcutaneous tissue is often bulky and is also excised (Figure 8)

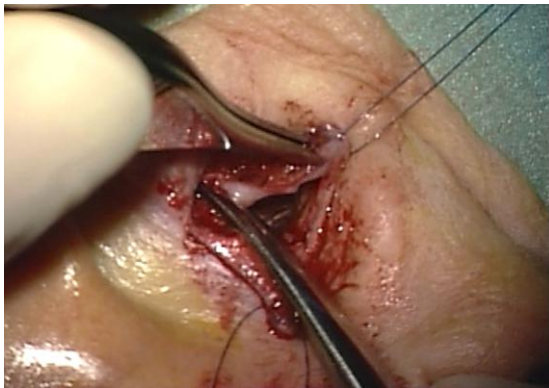


Figure 8: Subcutaneous tissue is excised

V-Y plasty

- A fourth 1cm transverse incision is made in the posterior canal wall, thus creating two intrameatal skin flaps (Figures 9 & 10)
- 6/0 Nylon sutures are used to suture the skin flaps as follows:
- Sutures are placed between the pointed ends of the two intrameatal skin flaps and either side of the base of the central triangular skin flap (Figures 11 & 12)

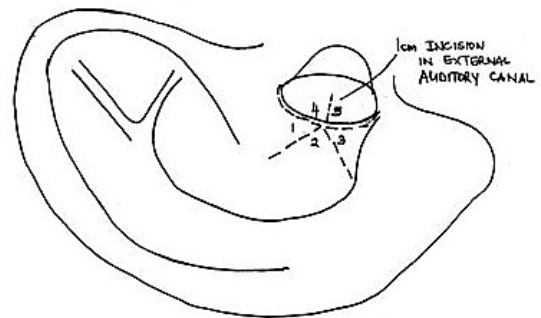


Figure 9

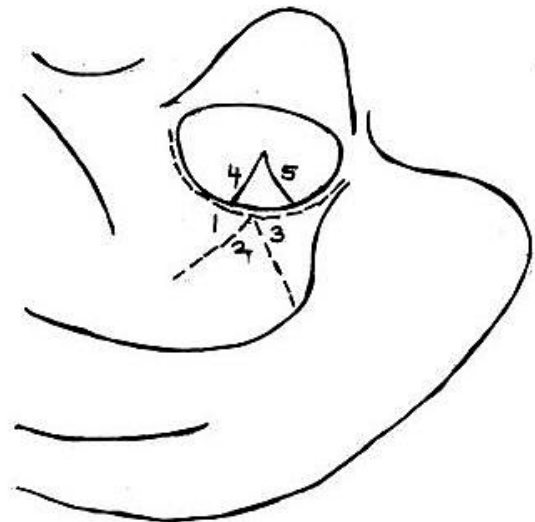


Figure 10

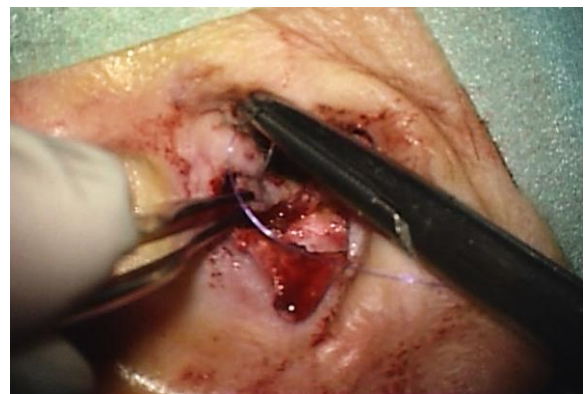


Figure 11: Sutures placed between ends of the intrameatal skin flaps

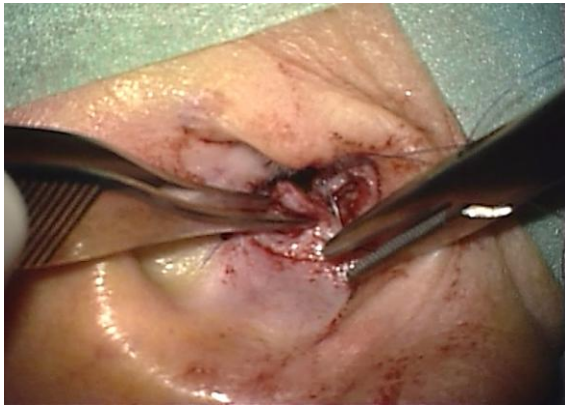


Figure 12: Sutures placed between ends of the intrameatal skin flaps

- A suture is placed at the beginning of the intrameatal skin incision and the apex of the middle triangular skin flap. This step widens the entrance of the external ear canal (Figure 13)

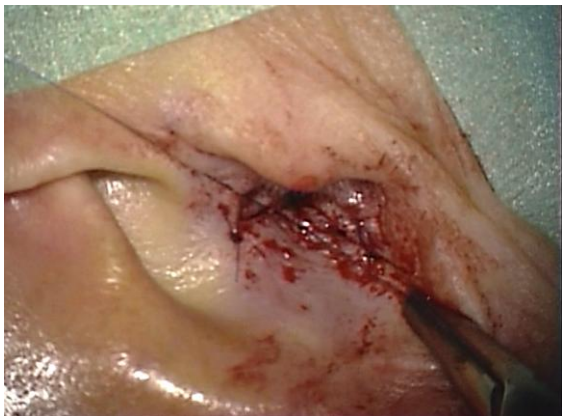

Figure 13: Suture placed at beginning of the intrameatal skin incision and apex of middle triangular skin flap

- The two redundant triangular skin flaps are excised, and sutures are placed between the remaining edges of skin of the *cavum concha* and the intrameatal skin flaps (Figure 14,15,16)
- This results in a scar shaped like an “M” (Figure 17)
- A *Terracortril* (ointment containing a steroid and antiseptic agent) gauze is placed in the external ear canal for 5 days
- Sutures are removed after 1 week

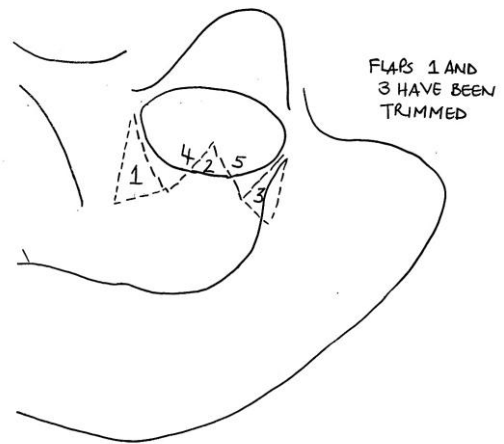


Figure 14

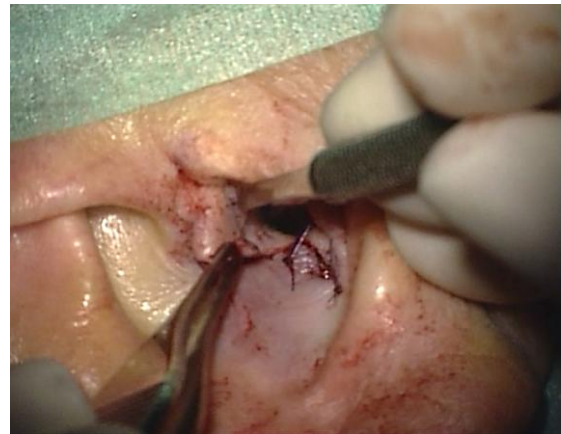

Figure 15

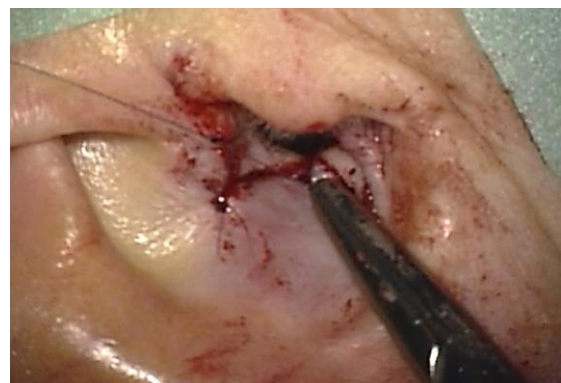


Figure 16

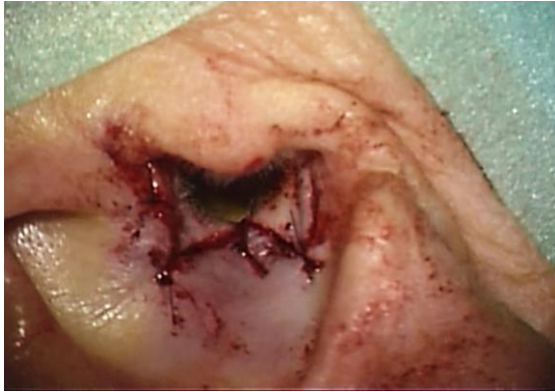

Figure 17

View meatoplasty video:

<http://youtu.be/jvSVteRkUO8>

References

1. Fisch U, May J, Linder T. Tympanoplasty, Mastoidectomy, and Stapes Surgery. New York: Thieme; 2008.
2. Mirck PG. The M-meatoplasty of the external auditory canal. *Laryngoscope*. 1996; 106(3):367-69.

How to cite this chapter

Harris, T, Linder T. (2012). Meatoplasty. In *The Open Access Atlas of Otolaryngology, Head & Neck Operative Surgery*. Retrieved from <https://vula.uct.ac.za/access/content/group/ba5fb1bd-be95-48e5-81be-586fbaeba29d/Meatoplasty.pdf>

Authors

Tashneem Harris MBChB, FCORL, MMED (Otol), *Fisch Instrument Microsurgical Fellow*
Associate Professor and ENT Specialist
Division of Otolaryngology
University of Cape Town
Cape Town, South Africa
harristasneem@yahoo.com

Thomas Linder MD
Professor, Chairman and Head of
Department of Otorhinolaryngology,
Head, Neck and Facial Plastic Surgery
Lucerne Canton Hospital, Switzerland
thomas.linder@ksl.ch

Editor

Johan Fagan MBChB, FCS(ORL), MMed
Emeritus Professor and past Chair
Division of Otolaryngology
University of Cape Town
Cape Town, South Africa
johannes.fagan@uct.ac.za

**THE OPEN ACCESS ATLAS OF
OTOLARYNGOLOGY, HEAD &
NECK OPERATIVE SURGERY**
www.entdev.uct.ac.za



The Open Access Atlas of Otolaryngology, Head & Neck Operative Surgery by [Johan Fagan \(Editor\)](mailto:johannes.fagan@uct.ac.za) johannes.fagan@uct.ac.za is licensed under a [Creative Commons Attribution - Non-Commercial 3.0 Unported License](https://creativecommons.org/licenses/by-nc/3.0/)

