

BONE ANCHORED HEARING IMPLANT/AID SURGERY (BAHI/BAHA)

Malou Hulcrantz

Bone anchored hearing implants/aids (BAHI/BAHA) utilise a bone anchored hearing aid system to assist people with conductive hearing loss who cannot use traditional hearing aids. It was introduced in the 1970's in the field of dentistry by Swedish Professor Per-Inge Brånemark who implanted titanium dental fixtures in the jaw. He then proceeded to develop titanium implants to anchor hearing aids to the skull with Dr Anders Tjellström, a Swedish ENT surgeon¹. The system comprises an osseointegrated implant, an abutment, and a processor (*Figures 1a, b*).

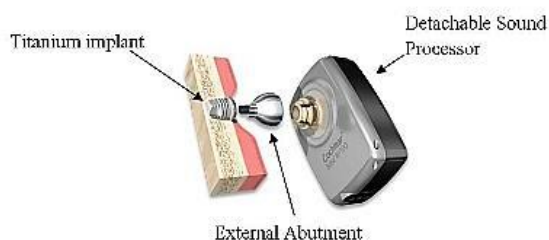


Figure 1a: Titanium fixture anchored in the bone with an abutment attached. The processor is connected to the abutment with a snap coupling.



Figure 1b: Titanium fixture with abutment

The fixture uses the characteristics of titanium to osseointegrate into bone. Bone cells (osteoblasts) adhere to the titanium surface of the implant without any other cells or capsules developing in-between. The biocompatibility of the metal is dependent on the titanium oxide layer on the surface of the implant and the lack of tissue interface between the bone and the titanium, all of which improve bone con-

duction of sound². The surface and shape of the implant and its abutment have since been refined. Different surfaces of the abutment have been tested and refinements continue.

Surgical techniques continue to evolve. Historically there was a long tradition of a "skin thinning technique". The idea was to minimise the depth of the skin down to the periosteum and to remove all subcutaneous tissue as well as hair roots to avoid bacterial penetration. The ideal thickness of the skin was recommended to be 0.2-0.5mm. In the early days a full skin transplant replaced the removed tissue, and the surgical procedure took up to 5 hours³. With new tools and new surgical flap techniques (semicircular flaps, dermatome, pre-drawn fixtures/abutments, one-step surgery *etc.*) the operating time was reduced to about 1 hour. The dermatome was introduced in 2006 to create a skin flap of predesigned thickness - a measure that also reduced the surgery time - but with the drawback that flap necrosis occurred more commonly⁴. The surgical procedure was further simplified by changing the surgical tools and implant design. Further refinements were introduced in 2007 when the skin thinning technique was replaced by a "non-skin thinning" or "tissue preserving" technique. Nowadays one simply makes small openings in the skin without skin reduction by punching a hole through which the abutment is externalised⁵. This requires longer abutments which are commercially available. This technique has reduced the surgical time to 10-15 min. The situation has also changed over the years in paediatrics; now the implantation is done in a single step in children⁶. The most recent development is implants placed under the skin with the processor connected via a magnet.

Physiology of bone conduction

The BAHA/BAHI employs direct percutaneous coupling of sound vibrations from a transducer to a titanium implant anchored in the skull. Hearing through direct bone conduction is defined as “sound transmission via bone conduction without the skin and soft tissue being part of the vibration transmission pathway between the transducer and the skull bone.” Direct bone conduction provides a sensitive input for vibrations to the skull, high-quality transmission of sound with sufficient gain and power output, and also improved patient comfort.

It is the cochlear function that is important; if sensorineural hearing is sufficient, then a bone-conduction hearing aid can transmit sound to the cochlea. The degree of conductive hearing loss is of minor importance since the bone-conducted sound bypasses the middle ear; the benefits of BAHA/BAHI are therefore independent of the external and middle ears⁷.

When an acoustic stimulus is presented to one ear there is a reduction in intensity of the sound perceived by the opposite ear. This phenomenon is called *interaural attenuation*. For air conduction, the reduction approximates 35dB, but for bone conduction, it is ≤ 10 dB. Consequently, the sound delivered with a bone-anchored solution is delivered to the opposite cochlea without much loss.

Hearing with two ears (*binaural hearing*) makes it possible to localise the source of a sound and to hear better in noisy environments. If one has only one hearing ear *i.e.* single sided deafness (SSD) or ear canal atresia *etc.*, the absence of a time lag between sounds reaching each ear means that one’s ability to localise the source of a sound is lost. The BAHI has been shown to

be of value when there is only one functioning cochlea with SSD; sound waves from the processor on the deaf side are transmitted to the contralateral functioning cochlea (*Figure 2*). However, even though binaural hearing will not develop if implanted in adulthood, it might be possible to achieve binaural hearing if the implant is placed early in childhood.

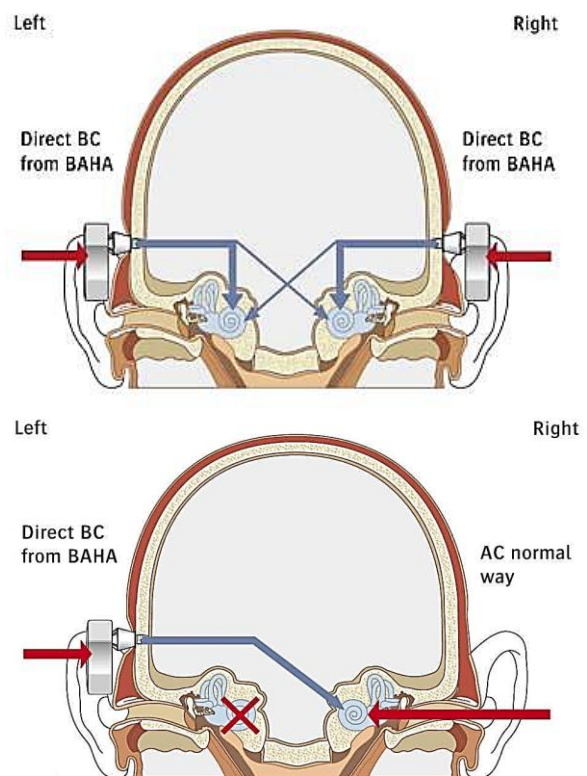


Figure 2: Sound conduction in the case of two normal cochleae (above) or with only a functioning right cochlea and left SSD

BAHA/BAHI

The BAHA/BAHI has 3 parts (*Figure 3*):

1. Titanium fixture introduced into the skull behind and above the pinna
2. Skin-penetrating abutment attached (screwed) to the fixture
3. Conventional microphone and amplifier (processor) connected by a snap coupling to the abutment



Figure 3a: Cochlear osseointegration system with coupling inside the abutment




Figure 3b: Oticon system: Left-to-right: Sound processor; Coupling; Screw; Abutment; Implant. The coupling is on the outside of the abutment

Patient selection

All patients who need a hearing aid but cannot have it fitted into the ear canal may benefit from a BAHI - within certain limits depending on the patient, implant and processor. Figure 4 and Table 1 and below show one of the more commonly used classification systems (*degree of hearing loss* = severity of loss). Many vendors recommend BAHI as a solution for patients with moderate-to-severe mixed hearing loss.

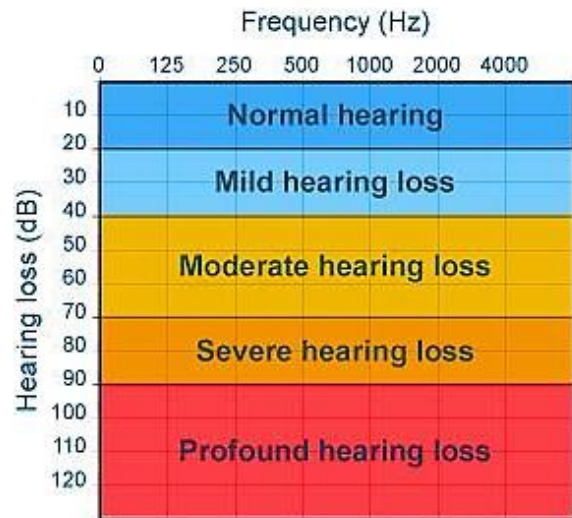


Figure 4: Classification of hearing loss

Degree of HL	Hearing loss (dB HL)
Normal	-10 to 15
Slight	16 to 25
Mild	26 to 40
Moderate	41 to 55
Moderately severe	56 to 70
Severe	71 to 90
Profound	91+

Table 1: Classification of hearing loss (HL)

To identify a suitable patient requires an audiogram with classification of type of hearing loss and at least a 3–4-week trial of a BAHI on a soft band at home and in working situations. If a patient is still interested to proceed after such a trial, surgery can be planned. This selection process hopefully reduces the number of future nonusers. The benefit is limited by inner ear “cochlear” function. However, even if a patient does not fall within the recommended domain of hearing loss, it may be worth a trial of a BAHI with a headband for 3 weeks. Some patients do benefit even if it is difficult to predict according to existing hearing tests.

Indications for BAHl include:

1. Conductive hearing loss, when using conventional hearing aids is impossible (ear canal problems, allergy to hearing aid material), or when hearing aids are contraindicated (ear must be kept dry) or ineffective
2. Mixed hearing loss (*both* conductive and sensorineural hearing loss)
3. Chronic otitis media, or chronic suppurative otitis media with otorrhoea (impossible to use a conventional hearing aid)
4. Congenital microtia or canal atresia (no ear canal for fitting)
5. Chronic otitis externa (skin problems)
6. Discomfort with conventional hearing aids (pain, moist, recurrent infection)
7. Ineffective conventional hearing aids due to considerable air-bone gap (not enough "gain", bad occlusion or feedback)
8. Single sided deafness (SSD); note that BAHl devices do not restore binaural hearing
9. Bilateral and single sided conductive hearing loss (CHL)
10. Bilateral hearing problems/infections where surgery is planned for the two ears at different times (hearing while waiting)

Selecting an appropriate BAHA/BAHI

Different devices are recommended in accordance with hearing loss and individual preference. General examples are given below.

Figure 5 illustrates the recommended hearing loss area for patients to benefit from Ponto processors & BAHA 4. Figure 6 illustrates the recommended hearing loss area for patients to benefit from a more powerful Ponto Pro Power® (Oticon)⁸ & Baha 3 Power® (Cochlear)⁹.

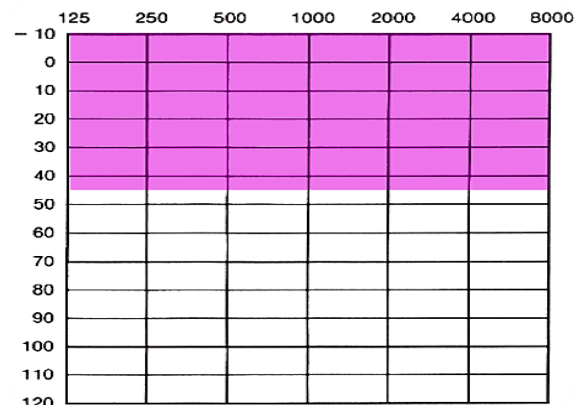


Figure 5: Hearing loss area for patients to benefit from Ponto processors (Oticon) & Baha 4 (Cochlear).

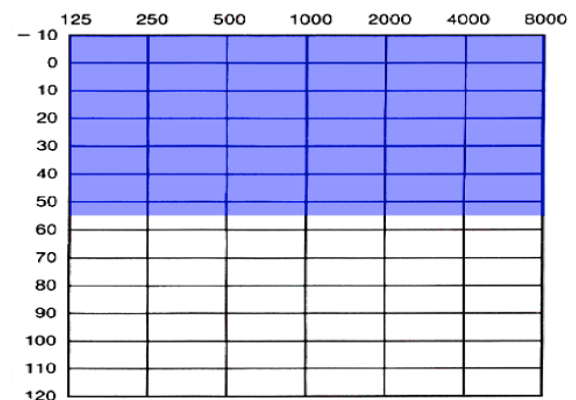


Figure 6: Ponto Pro Power® (Oticon)⁸ & Baha 3 Power Sound Processor® (Cochlear)⁹

Figure 7 illustrates the recommended hearing loss area for patients to benefit from a BAHl Cordell, which is the most powerful device and is body worn.

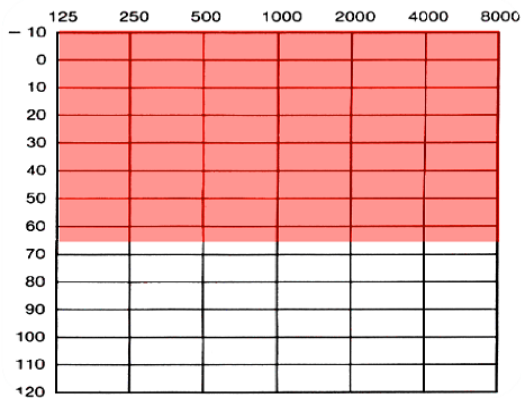


Figure 7: BAHI Cordell, the most powerful device and body worn

Surgical procedure

Older techniques that employ skin thinning are still used in many countries. However newer skin preservation techniques have proven to be safe in the long-term and have significant benefits¹⁰ *i.e.* reduced surgical time; quicker healing; earlier loading of the processor; less peri-implant infections; no numbness around the implant site; and normal hair cover (Figure 8).

Skin thinning technique

The older skin thinning technique (dermatome and variety of flap techniques) has been so frequently used all over the world and will only be briefly described. It is often performed under general anaesthesia and the surgical time about 45 min. The principal step is to raise a flap either with a dermatome or with a knife and to reduce

the subcutaneous tissue down to periosteum. This can also be achieved by totally removing a circle of skin for a new skin graft. The skin is thinned and hair follicles reduced; the hole in the skull bone is drilled; the implant with pre-drawn abutment is introduced; a hole is punched through the thinned skin where the abutment is externalised; and the wound is closed and dressed.

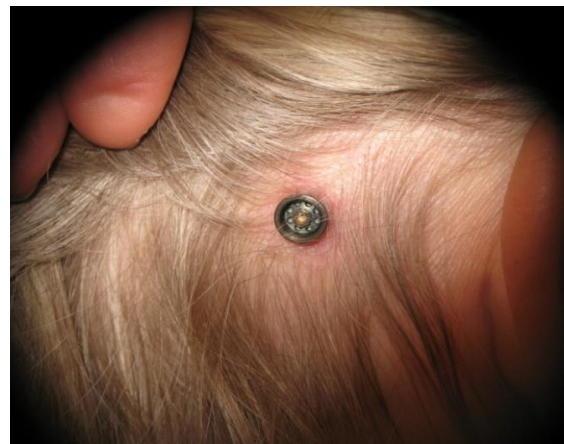

Figure 8: Normal hair cover 5 years after surgery

Linear incision with tissue preservation

- Most adult cases are done under local anaesthesia as an outpatient procedure with the head turned to the side; general anaesthesia can be done with a laryngeal mask (Figure 9)

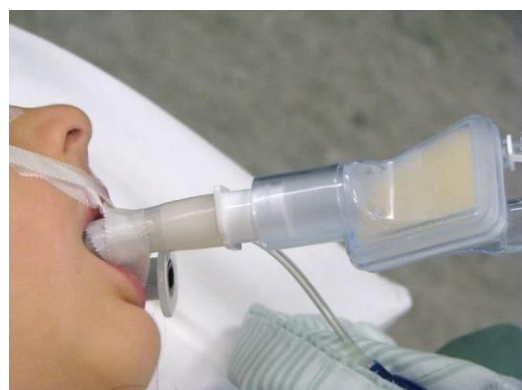

Figure 9: Patient anaesthetised with head in lateral position

- Clean the skin and drape the surgical area (*Figure 10*)

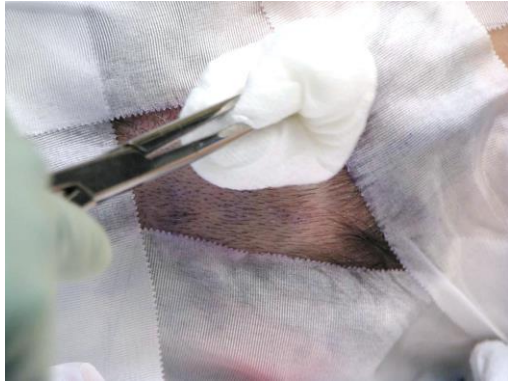


Figure 10: Washing and then redrawing so that the designated spot is visible

- Shave a small part of the surgical area if necessary
- Mark the position of the implant with dye *e.g.* methylene blue, approximately 5.5cm behind and above the opening of the external ear canal (*Figure 11*)

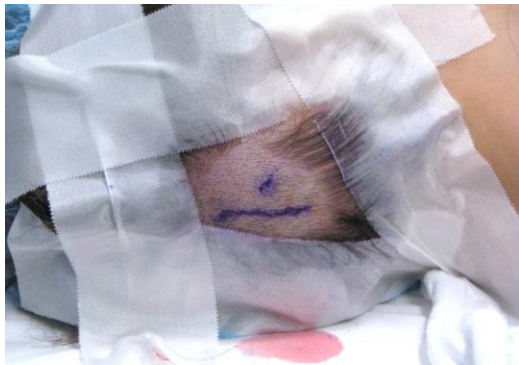

Figure 11: Blue mark indicates position of implant

- Take care to choose the right position if the patient wears glasses so that the processor will not interfere with the earpiece of the glasses; if an otoplasty is to be done in the future, the skin incision is placed in a more posterior location (*Figure 44*)
- Drape the patient (*Figures 12-17*)

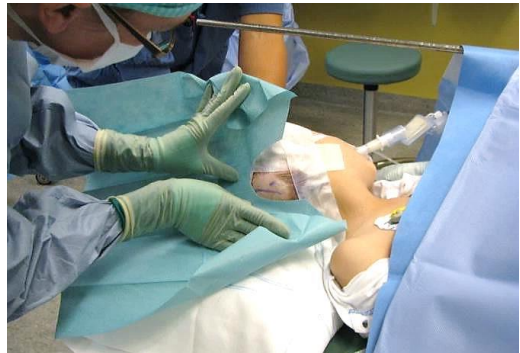

Figure 12: Cut a hole in the superior drape for the ear and surgical field

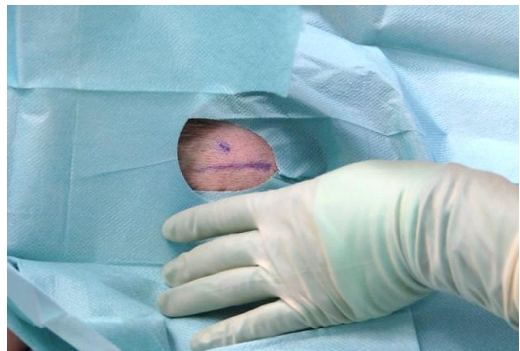


Figure 13: Cut a hole in the inferior drape for the ear and surgical field

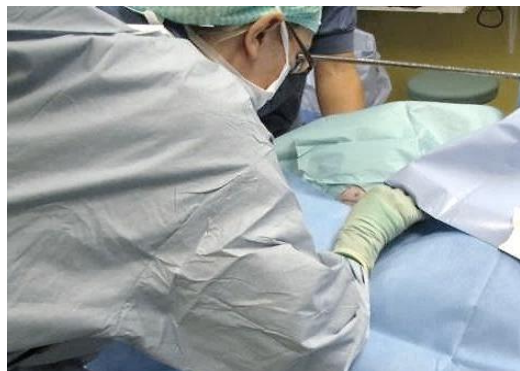

Figure 14: U-shaped sheets taped.....

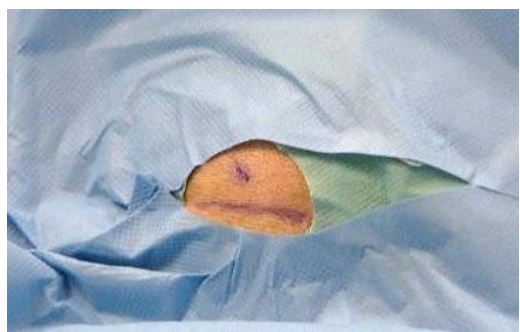

Figure 15:and pasted to the skin

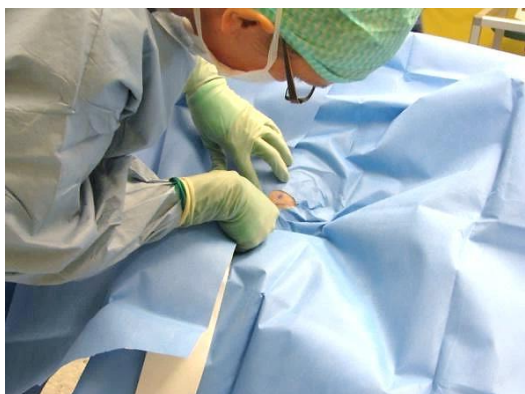

Figure 16: Apply an adhesive transparent plastic sheet (optional)

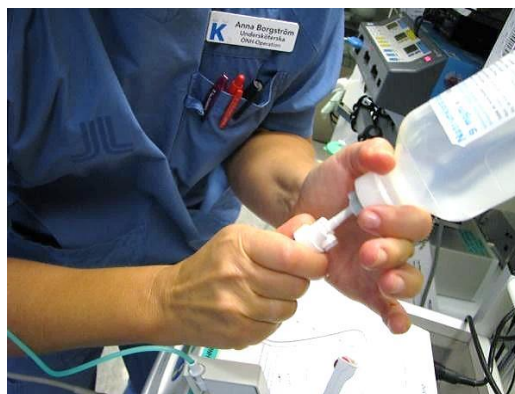

Figure 19: Attach the irrigation solution

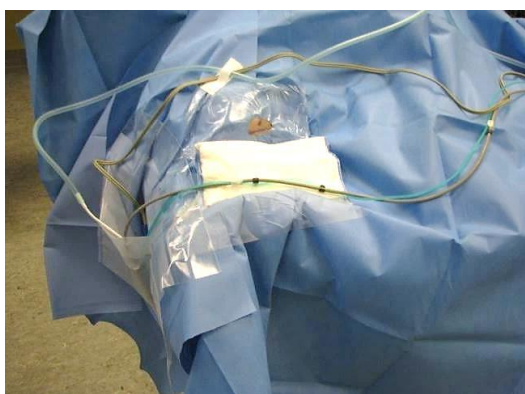

Figure 17: Final view of draped field

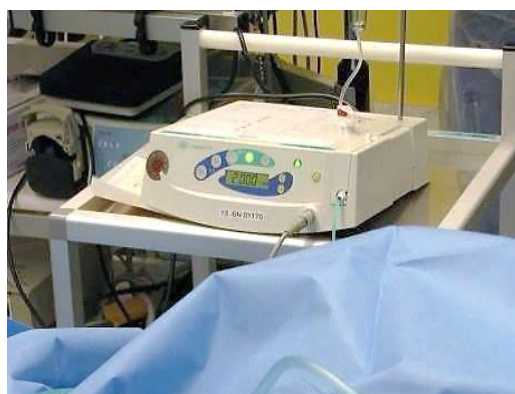

Figure 20: Set the drill speed

- Prepare the drill system (Figures 18-22)



Figure 18: Mount the drill irrigation tubing to the drilling machine (if such system is not available irrigate with a syringe filled with NaCl to cool the drilling of the bone)

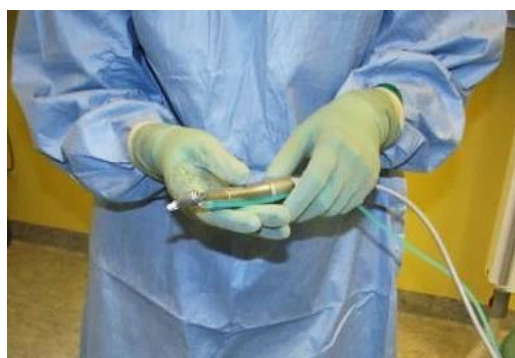

Figure 21: Check the drill and integrated irrigation system



Figure 22: Drill bits

- Set out the required instruments (*Figure 23*)

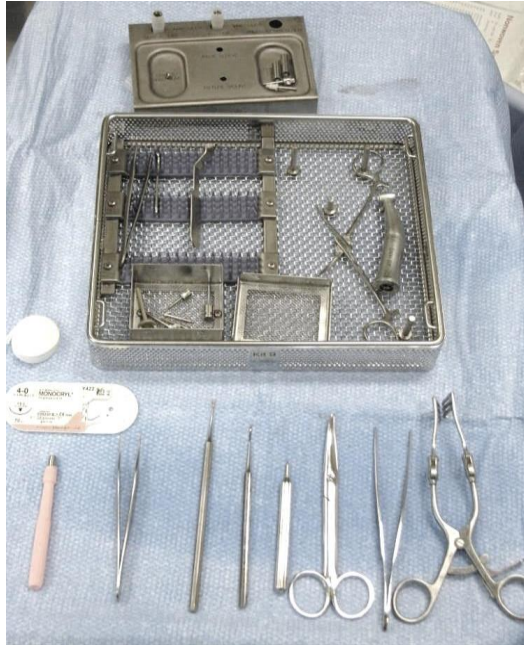

Figure 23: Instruments required

- Measure the skin thickness either now (or later as in *Figure 27*) with a needle through the blue marked spot, mark the depth and measure with a ruler
- Make a straight 30-40mm linear incision down to periosteum in front of the spot as indicated in *Figures 24, 25*
- Obtain haemostasis (*Figure 26*)
- Incise the periosteum



Figure 24: Straight 30-40mm linear incision down to periosteum

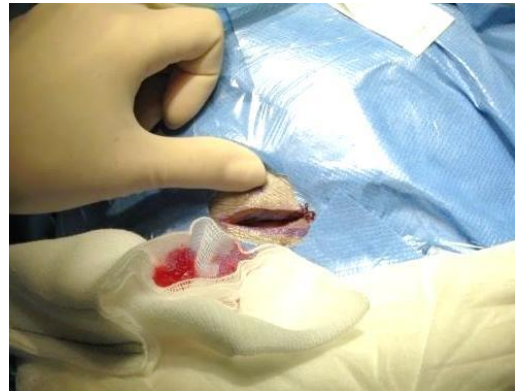

Figure 25 : Vertical 4cm incision down to bone

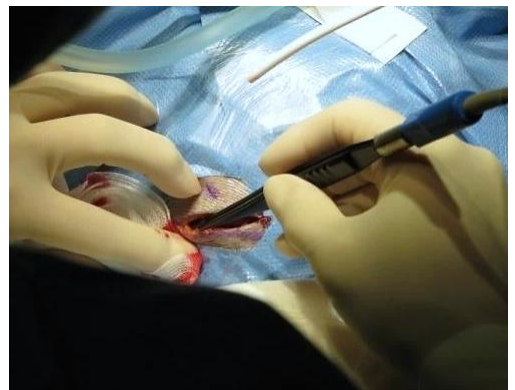

Figure 26: Use electrocautery for haemostasis

- Measure the skin thickness (*Figure 27*)
- Set the drill at 2000rpm (*Figure 28*)

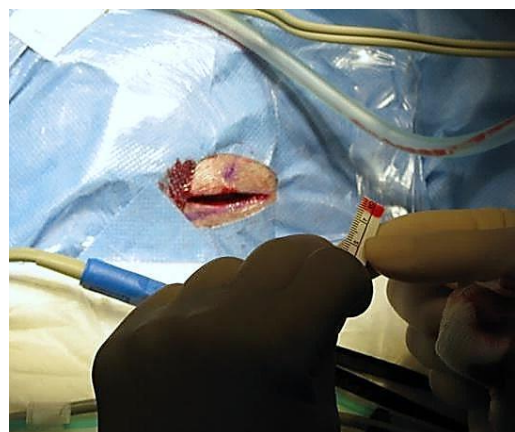


Figure 27: Measure the skin thickness

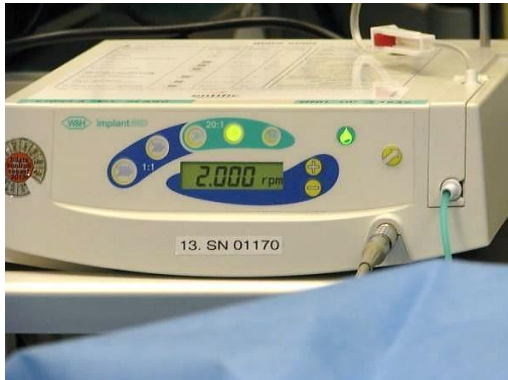

Figure 28: Drill setting for initial drill holes

- Drill a 3mm deep hole in the bone in the selected place with a high-speed drill (2000rpm) with a plastic “stopper” on (Figures 29, 30)
- If there is still bone in the bottom of the hole, remove the plastic stopper on the drill piece and continue drilling until the next stop is reached and a 4 mm depth is achieved. This allows a 4mm fixture to fit into the hole with good stability for the abutment (Figure 29, 30)

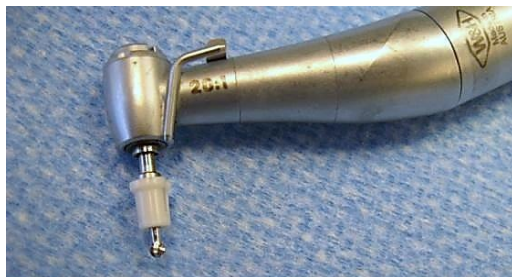

Figure 29: 3 mm drill bit with plastic “stopper”

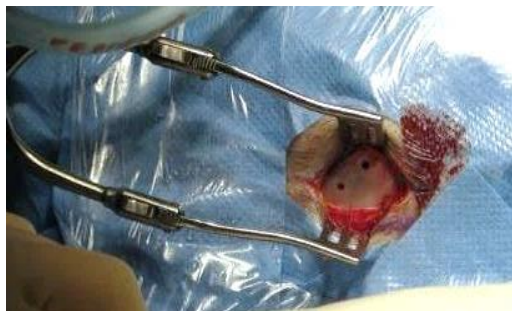


Figure 30: Note: 2nd hole is drilled in children for a “sleeping fixture”

- Widen the drill hole with a “countersink” burr, still at 2000 rpm drill speed (choose a 3 or 4 mm countersink depending on the depth of the burr hole) (Figures 31, 32)

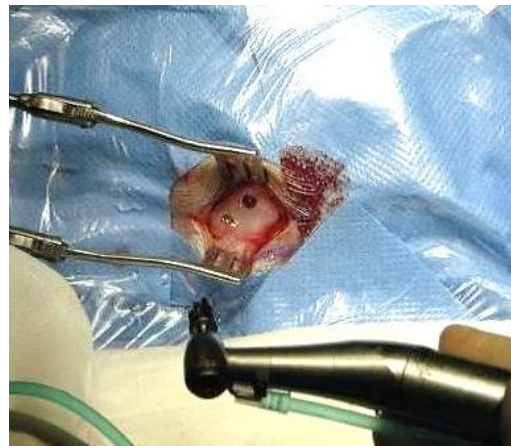


Figure 31: One hole has been enlarged with the countersink drill (child)

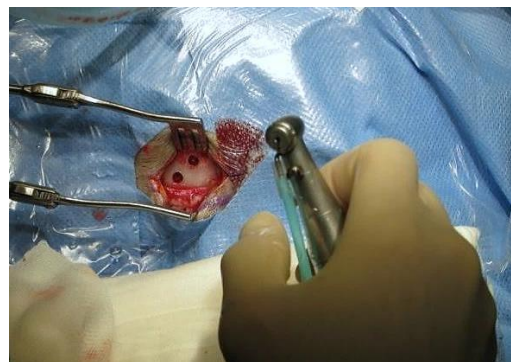


Figure 32: Both holes have been enlarged (child)

- Select the correct fixture according to the drill hole (3 or 4 mm) and the predrawn correct abutment according to the skin thickness (6-12 mm long)
- Set the drill at a low speed and at a power setting of 40-50 Ncm (adults, and ca 25 Ncm for children) (Figure 33)
- Set the drill at a low speed and at a power setting of 40-50 Ncm (Figure 34)
- Screw the fixture into place (Figure 35)



Figure 33: Drill setting for inserting the fixture




Figure 36: Punching a hole in the skin

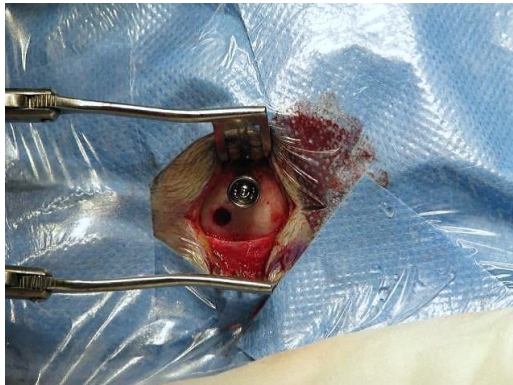

Figure 34: Fixture screwed into bone

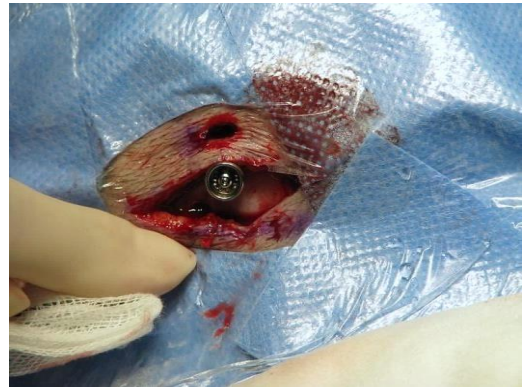

Figure 37: Punch a hole through the skin and apply a cover screw to the 2nd fixture in children

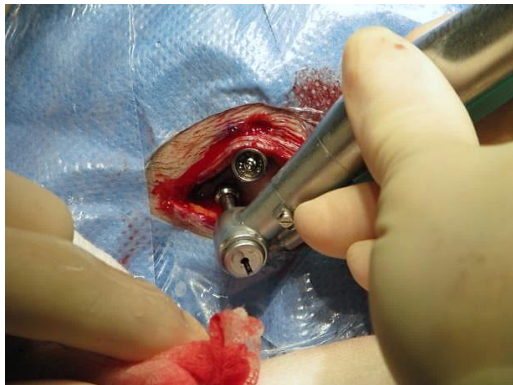

Figure 35: 2nd fixture being inserted (child)

- Punch a hole in the skin at the marked place with a 5mm diameter skin punch (Figures 36, 37)
- Externalise the abutment through the hole (Figure 38)
- Close the skin with resorbable subcuticular sutures (Figure 38, 39)

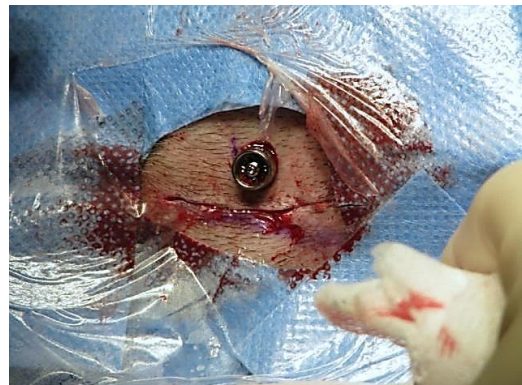

Figure 38: Pass the abutment through the hole in the skin

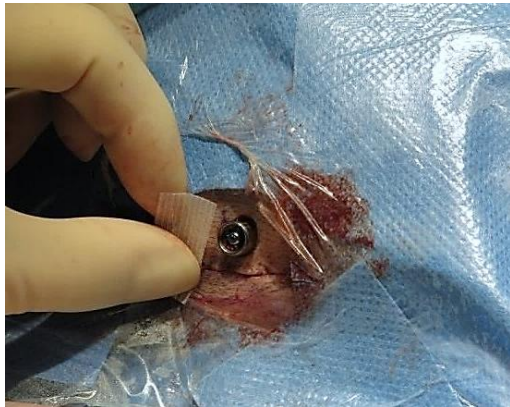

Figure 39: Taping the incision

- Attach a healing cap to the abutment (Figure 40)

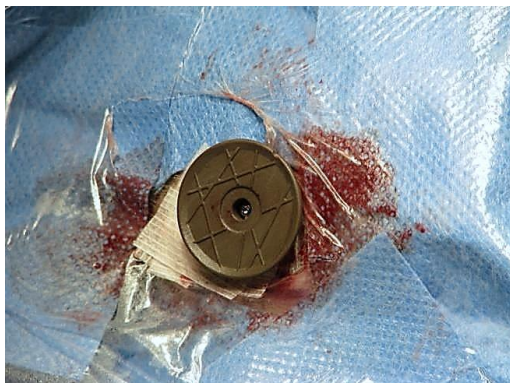


Figure 40: A healing cap is applied

- Gently wind gauze impregnated with antibiotic ointment around the abutment and under the cap (Figure 41)

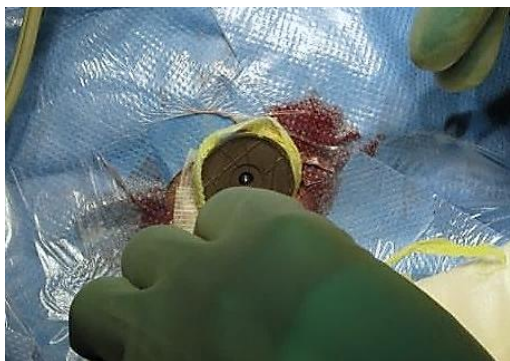

Figure 41: Terracortril ribbon gauze rolled under the healing cap

- Place fluffed gauze over the wound and apply a head bandage (Figures 42, 43)

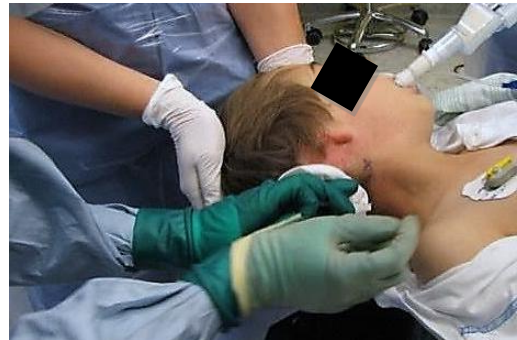

Figure 42: Fluffed gauze is placed over the wound

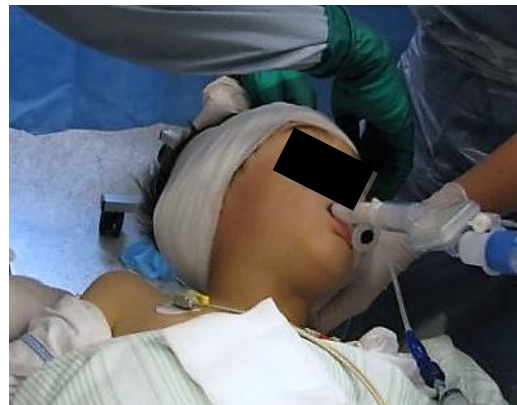

Figure 43: Apply a head bandage

- Remove the healing cap after 7-10 days together with the gauze
- The processor can be loaded to the abutment after another 2-4 weeks^{5, 11}

Video of surgical technique of linear incision with tissue preservation:

<https://www.youtube.com/watch?v=7lQsaV6GTA8>

Biopsy punch technique (Figures 44a, b)

- Mark the implant site
- Measure the skin thickness with a needle
- Inject local anaesthesia
- Remove the skin and soft tissue with a wide punch down to periosteum
- Drill a hole in the bone through the punch hole to an appropriate length (3 or 4mm)

- Introduce the pre-drawn fixture with an abutment of the correct length
- No suturing is required unless a very wide punch (12mm) has been used¹²
- Note: The emissary veins in the bone can bleed briskly when drilled into, so always be prepared for this event *e.g.* open the skin wider, bone wax *etc.*




Figure 44a: Removing skin and soft tissue (also the periosteum) with a wide punch




Figure 44b: Abutment in place (With permission from Oticon Medical)

Surgical procedures in children

If a child is born with severe hearing loss, single or double-sided atresia or SSD, it is recommended to refer the child to an audiological centre early. Testing with a BAHI on a soft band can then be done and the BAHI fitted later (Figure 45).

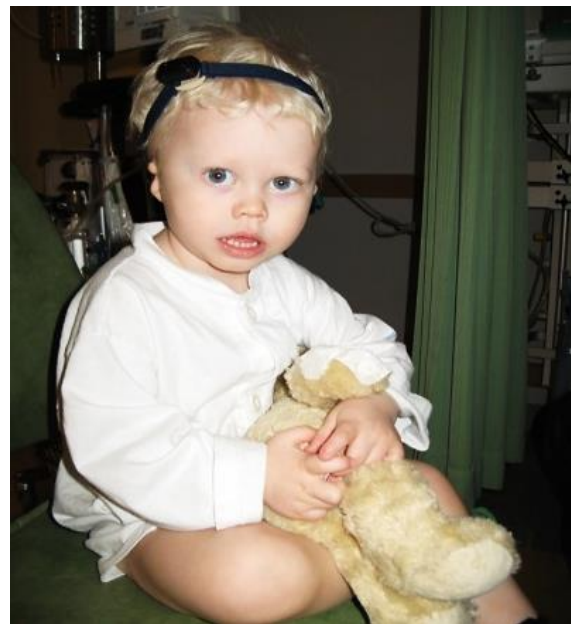

Figure 45: BAHI on a soft band

With atresia, outer ear reconstruction is recommended when enough rib cartilage has developed at the age of 5-10 years. Outer ear canal reconstruction can be considered when children are able to decide for themselves (14-16 years of age). If a new ear canal has been surgically constructed the child needs to see an ENT specialist every 6-12 months to clean the ear canal to avoid retention of debris and development of cholesteatoma. There is a trend today to avoid the difficult surgery to reconstruct the ear canal, since the results have not been good enough, and instead to reconstruct an outer ear in a cosmetically acceptable way and to use a BAHI for hearing. Children with double-sided atresia must use a BAHI on a soft band from a young age (3 months) for language acquisition, whereas others should start as soon as possible, and always 3-4 weeks before a decision is made to operate.

Children with single-sided atresia benefit from training the hearing pathways early on the atretic side. Previously no rehabilitation was given to these children since they developed speech normally. However, in the busy society of today it has been

shown that these children will have problems later on and that the earlier they are fitted with a BAHI the better. A headband at an early age gives the child the possibility to get used to binaural hearing. Reports show that as many as 1/3 of these children need to repeat one year at school and that every other child needs extra resources during schooling. Some children with single-sided atresia, even if they do not have other syndromes, will never develop strategies to cope with their hearing handicap¹³.

A permanent fixture and abutment for the bone conducting hearing aid is easier to utilise for a child than a headband and also gives better hearing. The time at which to introduce the permanent fixture can be decided when the skull bone thickness is ≥ 2.5 mm, which is usually around the age of 2,5 - 3 years.

BAHI surgery in children is usually done under general anaesthesia. The procedure can be performed as a 1-stage or a 2-stage procedure depending on how thick the skull bone appears to be at surgery. If the bone is ≥ 2.5 -3mm thick, then surgery can be performed as a 1-stage procedure in the same manner as described for adults. If the skull is thinner, a 2-stage procedure is preferable.

Two fixtures are usually placed in the bone in children; one is used with the abutment and the 2nd as a sleeping “rescue fixture” to be used if the 1st implant is removed after trauma or infection (*Figure 46*). (In such cases one simply needs to punch through the skin overlying the sleeping fixture as the implant is already osseointegrated). The 2 fixtures are introduced, and the skin is closed. The system is left undisturbed for 2-3 months for osseointegration to occur. At the 2nd surgical stage, the skin over the selected fixture is punched out and the abutment is introduced under gene-

ral anaesthesia. The processor is loaded quite soon thereafter⁶ (*Figure 47*). It is recommended that the child uses a “safe line” to attach the processor to his/her clothes in order not to lose the processor.

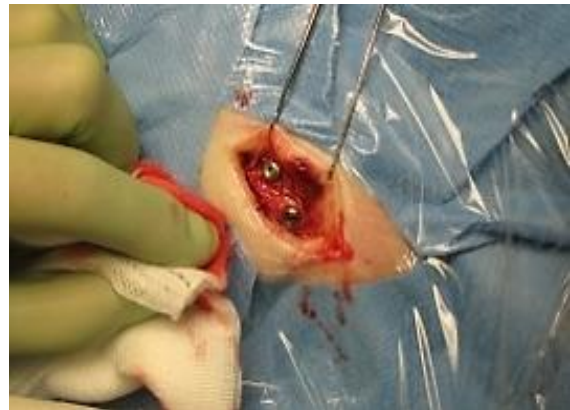

Figure 46: Two fixtures placed in the skull

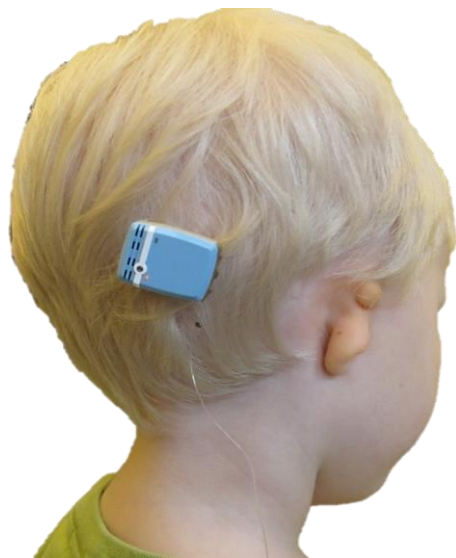

Figure 47: Processor placed a bit further back due to pending outer ear reconstruction

Loading the sound processor

Two manufacturers currently produce BAHA/BAHI fixtures and abutments. The Cochlear processor only fits onto the Cochlear abutment⁸, while both the Oticon and Cochlear processors fit onto the Oticon abutment⁹ allowing the patient and audiologist the flexibility to select the processor best suited to the individual's hearing loss.

Once the fixture has osseointegrated after 2-3 weeks, the audiologist or audiology technician fits the processor according to the individual audiogram using the corresponding software program. Usually, 2-3 appointments with the audiologist are required to adjust and tune the processor to optimise the sound perception.

New better processors are constantly being released with new features *e.g.* streamers, that make it possible to direct sound from a mobile telephone directly to the aid.

Complications

Problems encountered with percutaneous (implant passes through skin) systems include peri-implant infection, loss of the abutment (infection or trauma), cosmetic factors, skin numbness and the fact that the skin needs lifelong daily care *etc.*

Peri-implant infection

Peri-implant infections occur commonly around the abutment (*Figure 48*). The *Holgers classification system* grades soft tissue reactions at the implant site ¹⁴:

Grade 1: Redness with slight swelling around the abutment

Grade 2: Redness, moistness and moderate swelling

Grade 3: Redness, moistness and moderate swelling with tissue granulation around the abutment

Grade 4: Overt signs of infection resulting in removal of the implant

Infection can be avoided if the correct skin care is applied daily. Cleaning the skin around the abutment is an important task for the patient who must learn the signs and properties of their skin. Recommended tools for skincare are a soft toothbrush to clean the abutment site, water and soap,

the correct type of hair shampoo and an ointment if the skin is dry.

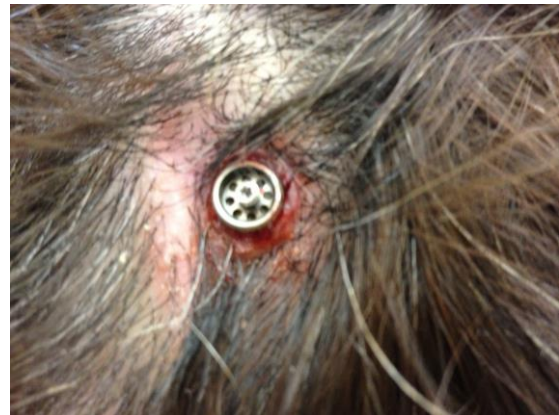

Figure 48: Peri-implant infection

If infection is noted, then more intensive cleaning is necessary and an ointment with antibiotics should be applied. Cauterising agents like silver nitrate can be used on the skin for granulation tissue around the abutment and oral antibiotics can be prescribed if a bacteriological sample shows any growth. The abutment must be removed only if the infection persists (uncommon) to get rid of the infection and to allow the skin to heal. The osseointegrated fixture can be used again at a later stage. Such infections are less troublesome and recurrent if new skin preserving surgical techniques are used.

Skin pockets

The area close to the abutment can deepen, creating a skin pocket. Such pockets can be difficult for a patient to clean and meticulous skin care necessary in such cases is difficult for health care centres to provide. Deep skin pockets are seldom seen with the newer surgical techniques.

Poor osseointegration and fixture loss

This can be due to infection, biological factors, poor bone quality *etc.* and starts early after implantation or later after a first successful osseointegration. Surgical re-

sion is required once the skin has healed after removal of the fixture.

Flap necrosis

This is seen if a procedure creating a thin skin flap has been used, and delays healing. This problem is not often encountered if the skin is preserved.

Numbness around the abutment

If wide subcutaneous tissue removal is done as with the surgical flap technique, nerves supplying the skin are destroyed and permanent numbness in an area of up to 10cm may ensue. Numbness is a minor issue and is seldom seen with the modern techniques; it may be confined to only a small area around the abutment.

Deep pain

Hyperaesthesia sometimes occurs around the abutment. If deeper pain occurs from bone, it may be necessary to drill out the osseointegrated fixture.

Traumatic loss of abutment/fixture

Any direct trauma to the head and the implant area may lead to a loss of the implant. The skin heals over the fixture extremely quickly (1-2 days). If only the abutment is lost, a new abutment can be introduced as an outpatient procedure under local anaesthesia through a newly punched hole. If the entire fixture is lost, then a new surgical procedure must be done in adults. In children the sleeping fixture can be used for fixation of a new abutment.

Skin overgrowth (Figure 48)

With earlier flap techniques when the skin was extensively thinned and only 5.5mm abutments were available, skin at times

overgrew the abutment and prevented good connection with the processor.

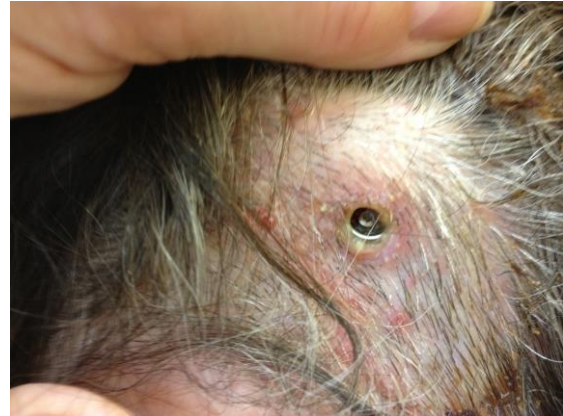

Figure 48: Skin overgrowth over the abutment which makes it impossible to use the processor

In children, new bone formation under the reduced skin was common and caused skin overgrowth. Another surgery was then necessary to thin the skin again and eventually drill some bone away. Skin overgrowth is less problematic today as skin thinning is not done and with the availability of a range of abutments that allow one to unscrew an abutment that is too short and replace it with a longer one; this can be done also in children as an outpatient procedure without any local anaesthesia.

New implants on the market

Four new implants were recently released as described below, and another is soon to be released (BCI, Oticon) that is implanted under the skin to avoid skin-related problems.

Sophono Alpha 2® (Sophono): This is a magnetically coupled bone anchored hearing device without an external abutment¹⁵. The abutment is placed under the skin (*Figure 50*). The system can only be used for mild hearing loss.



Figure 50: Sophono Alpha 2®

Bonebridge® (MedEl): This is an active BAHl placed under the skin. The vibrator (9mm diameter) is buried deep into the mastoid bone and requires extensive drilling to be fitted. The vibration is transferred through 2 screws that attach the vibrator to the bone. Patients must have a CT scan performed before surgery to determine whether the mastoid bone can accommodate the implant. It is MRI compatible ¹⁶ (Figure 51).



Figure 51: The Bonebridge® vibrator is placed into the mastoid

Baha 4 Attract® (Cochlear): The sound processor attaches to an external magnet, which transmits the sound to an internal magnet hidden under the skin. The magnet is attached to the implant, which delivers vibrations through the skull to the cochlea. The surgery can be performed under local anaesthesia. The implant is not MRI compatible ⁹ (Figure 52).



Figure 52: Baha 4 Attract®: The two implant components are deep to skin

SoundBite® (Sonitus Medical): This is a non-surgical hearing solution using bone conduction transmission via the teeth ¹⁷ (Figure 53).



Figure 53: Soundbite® attached around the teeth

Even with the many new innovations to come, the standard BAHl that penetrates the skin will still have its place as it is a quick surgical procedure performed under local anaesthesia and is a reliable aiding solution.

Instructional video

Linear incision with tissue preservation surgery technique:

<https://www.youtube.com/watch?v=7lQsaV6GTA8>

References

1. Tjellström A, Håkansson B, Lindström J, et al. Analysis of the mechanical impedance of bone-anchored hearing aids. *Acta Otolaryngol* 1980; 89: 85-92
2. Albrektsson T, Brånemark PI, Hansson HA, et al, Osseointegrated titanium implants: requirements for ensuring a long-lasting direct bone-to-implant anchorage in man. *Acta Orthop Scand* 1981; 52: 155-70
3. Håkansson B, Lidén G, Tjellström A, et al. Ten years of experience with the Swedish bone-anchored hearing system. *Ann Otol Rhinol Laryngol Suppl.* 1990 Oct;151:1-16
4. Stalfors J, Tjellström A. Skin reactions after BAHA surgery: a comparison between the U-graft technique and the BAHA dermatome. *Otol Neurotol.* 2008 Dec;29(8):1109-14
5. Hulcrantz M. A clinical trial using the bone-anchored hearing aid (Baha) method without the skin thinning step. *Otol & Neurotol* 2011;32(7):1134-9
6. Lanis A, Hulcrantz M. Percutaneous osseointegrated implantation without skin thinning in children: A retrospective case review. *Otol Neurotol* 2013; 34 (4):715-22
7. Eeg-Olofsson M, Stenfelt S, Taghavi H, et al. Transmission of bone conducted sound - correlation between hearing perception and cochlear vibration. *Hear Res.* 2013 Dec;306:11-20
8. <http://www.cochlear.com/wps/wcm/connect/sv/home>
9. <http://www.oticonmedical.com/>
10. Hulcrantz M, Lanis A. A five year follow-up on the osseointegration of bone-anchored hearing aid implantation without tissue reduction. *Otol Neurotol.* 2014 (In press)
11. Hulcrantz M. Linear incision surgery with tissue preservation. Educational film 2012
12. Goldman RA, Georgolios A, Shaia WT. The punch method for bone anchored hearing aid placement. *Otolaryngol Head Neck Surg* 2013;148:878-80
13. Cho Lieu J. Speech, language and educational consequences of unilateral hearing loss in children. *Acta Otolaryngol Head Neck Surg,* 2004;130:524-30
14. Holgers KM. Soft tissue reactions around clinical skin-penetrating titanium implants. PhD thesis, ISBN 91-628-1334-X. Gothenburg University, Gothenburg, Sweden, 1994
15. <http://sophonon.com/>
16. <http://www.medel.com/int/vbb>
17. <http://www.sonitusmedical.com/product/>

Author

Malou Hulcrantz MD, PhD
Professor
Department of Otolaryngology
Karolinska University Hospital
Stockholm,
Sweden
Malou.Hulcrantz@ki.se

Editors

Claude Laurent MD, PhD
Professor in ENT
ENT Unit
Department of Clinical Science
University of Umeå, Umeå, Sweden
claude.laurent@ent.umu.se

De Wet Swanepoel PhD
Professor
Department of Communication Pathology
University of Pretoria
Pretoria, South Africa
dewet.swanepoel@up.ac.za

Johan Fagan MBChB, FCS (ORL), MMed
Emeritus Professor and Past Chair
Division of Otolaryngology
University of Cape Town
Cape Town, South Africa
johannes.fagan@uct.ac.za

How to cite this chapter

Hultcrantz M. (2019). Bone anchored hearing implant (aid) (BAHI) (BAHA) surgery. In *The Open Access Atlas of Otolaryngology, Head & Neck Operative Surgery*. Retrieved from <https://vula.uct.ac.za/access/content/group/ba5fb1bd-be95-48e5-81be-586fbaeba29d/Bone%20anchored%20hearing%20implant%20aid%20BAHI%20BAHA%20surgery.pdf>

THE OPEN ACCESS ATLAS OF OTOLARYNGOLOGY, HEAD & NECK OPERATIVE SURGERY
www.entdev.uct.ac.za



The Open Access Atlas of Otolaryngology, Head & Neck Operative Surgery by [Johan Fagan \(Editor\) johannes.fagan@uct.ac.za](mailto:johannes.fagan@uct.ac.za) is licensed under a [Creative Commons Attribution - Non-Commercial 3.0 Unported License](https://creativecommons.org/licenses/by-nc/3.0/)

